

# Treatment of Infantile Fibrosarcoma in the Era of Targeted Therapies

Ulku Miray YILDIRIM<sup>1</sup>, Rejin KEBUDI<sup>1</sup>, Fikret ASARCIKLI<sup>2</sup>, Banu OFLAZ SOZMEN<sup>2</sup>,  
Ekrem UNAL<sup>3</sup>, Alper OZCAN<sup>3</sup>, Bulent ZULFIKAR<sup>1</sup>

<sup>1</sup> Istanbul University, Oncology Institute, Division of Pediatric Hematology and Oncology

<sup>2</sup> Koc University Hospital, Division of Pediatric Hematology and Oncology

<sup>3</sup> Erciyes University Faculty of Medicine, Department of Pediatrics, Division of Pediatric Hematology Oncology

## ABSTRACT

Infantile fibrosarcoma (IFS) is a very rare pediatric soft tissue sarcoma (STS). Resection with negative surgical margins without causing morbidity is the mainstay of treatment. When primary surgery is not possible, satisfying results can be obtained with conventional chemotherapy and targeted therapy. We aimed to evaluate the demographic, clinical, laboratory and radiological characteristics and treatment outcomes of pediatric patients with IFS. We retrospectively reviewed medical records of the patients diagnosed with IFS 1990 and 2022. The mean age at diagnosis of 12 patients was 90 days. The most common tumor localization was extremity. None of the patients were metastatic at diagnosis. Primary surgical excision was performed in five patients; three of them had positive surgical margins and two of these patients experienced recurrence. Surgical margins were negative in other two patients who were operated on, and recurrence occurred in one of them. Of the seven patients treated with primary chemotherapy, two patients had complete response, surgery was not performed. Larotrectinib was initiated to three patients with NTRK fusions. At a median of 104-month (7-206) follow-up, all patients are alive. Nine of the twelve patients survived disease-free for a median of 118 months (25-206). Although surgical resection is the mainstay of treatment of infantile fibrosarcoma, satisfying results can be obtained with chemotherapy and targeted therapy in inoperable cases. The use of targeted therapies can be increased by conducting molecular studies, especially in cases not suitable for surgery with a goal of avoiding side effects of conventional chemotherapy.

**Keywords:** Infantile fibrosarcoma, NTRK, Larotrectinib, Targeted therapy

## INTRODUCTION

Infantile fibrosarcoma (IFS) is a very rare pediatric soft tissue sarcoma (STS) and it is more common in infants with a recently reported 5-year event-free survival (EFS) and overall survival (OS) of 81% and 98% respectively.<sup>1-3</sup> Generally IFS is located in the distal extremities and tends to grow rapidly followed by a later more indolent process. Although local recurrence is common, survival rates are over 80% in children unlike adult counterparts.<sup>4,6</sup>

Most cases harbor the ETV6–NTRK3 gene fusion resulting from t(12;15) (p13;q25), while rare cases

involving other partners such as EML4-NTRK3 have been reported.

Although surgery is the mainstay of treatment, 50-60% of cases are unresectable at diagnosis.<sup>7</sup> In unresectable tumors, chemotherapy is recommended to shrink the tumor to allow a nonmutilating complete surgery.<sup>5,8</sup> In relapse/refractory cases, targeted treatment with neurotrophic troponomyosin receptor kinase (TRK) inhibitors have been shown to be quite effective in the treatment of patients with NTRK gene rearrangements.<sup>9-12</sup>

The aim of this study is to evaluate the demographic, clinical, laboratory and radiological characteristics, treatment and outcome of pediatric patients with IFS treated or consulted in a single center.

## METHODS

Medical records of children with IFS diagnosed between 1990 and 2022 at the pediatric oncology clinic of a referral hospital were retrospectively reviewed. Three cases who were consulted and followed-up in collaboration with two other centers. Demographic, clinical and radiological characteristics, treatment and outcome of the patients were evaluated. Follow-up time was recorded as the period from diagnosis to February 2023 or until the last visit. All patients were diagnosed histopathologically. In recent years, the ETV6-NTRK3 fusion and NTRK fusions with other counterparts were investigated by fluorescence in situ hybridization (FISH) and real time polymerase chain reaction (RT-PCR).<sup>13-15</sup>

Nonmutilating surgical complete resection was performed whenever possible. In unresectable cases or in cases where surgery would lead to unacceptable morbidity, diagnosis was established by a trucut biopsy and neoadjuvant chemotherapy was initiated. In cases with incomplete resection, chemotherapy was used postoperatively. Chemotherapy consisted of vincristine (V), actinomycin-D (A) + cyclophosphamide (C). [Vincristine 0.025 mg/kg for <12 months, increasing gradually up to 0,05 mg/kg; actinomycin-D 22.5 microgr/kg for <12 months, increasing gradually up to 45 microgram/kg; cyclophosphamide 25 mg/kg for <12 months gradually increasing to 40 mg /kg].

In recent years, larotrectinib has been considered as targeted therapy for relapsed/refractory cases in which molecular studies revealed a NTRK fusion.

The patients were evaluated by physical examination, complete blood count and biochemical tests before and during treatment and as necessary. None of the patients received radiation therapy. The study was approved by the institutional review board. Consent was obtained from parents.

Ethical approval was obtained from Istanbul University Oncology Institute Ethical Committee (1627478; 03.02.2023).

## Statistical Analyses

Statistics were calculated using IBM SPSS® 26 (Armonk, New York, U.S.). Kaplan-Meier method was used for survival analysis. Overall survival was calculated from the date of diagnosis to the date of last information on follow-up or death. Event-free survival was calculated from the date of diagnosis to the date of first event, such as progression, relapse, or death from any cause.

## RESULTS

Twelve patients (eight male, four female) were diagnosed with IFS. The median age at diagnosis was 90 days (range 7-360 days). Two patients were diagnosed in the neonatal period. Extremities were the most common tumor primary site (nine patients, 75%) followed by scapula, cervical and thoracic region (one patient each). The presenting sign was a soft tissue mass in all patients. None of the patients were metastatic at diagnosis. Patient characteristics are summarized in Table 1.

The diagnosis was established after surgical resection in four patients and with trucut biopsy in eight. Primary surgical excision was performed in five patients. Surgical margins were negative in two patients (both located in lower extremities) in whom the tumor was totally resected. One is under follow-up with NED without any further treatment. In the other, local recurrence occurred four months after the first surgery. He received chemotherapy (VAC) and underwent a complete resection and is with NED).

Three of the patients with primary surgery had positive surgical margins. One of these patients with a tumor in scapular region was reoperated with negative surgical margins four months after the first operation and is under follow-up with no evidence of disease (NED) without any further treatment. Two of the three patients having tumors in thoracic and cervical region with positive surgical margins experienced recurrence in the first and second months

**Table 1.** Patient characteristics

Patient no	Age at diagnosis (days)	Gender	Tumor localisation	NTRK fusion	Treatment	Margin status of first surgery	Recurrence/ Progression	Subsequent treatments	Outcome/ Duration of FU/ Disease-free FU (months)
1	45	F	Left lower extremity	NA	1xVAC, 10xVA	No surgery	No	No	NED /206/198
2	30	M	Right lower extremity	NA	2xVA,8xVAC	No surgery	No	No	NED /155/146
3	27	M	Cervical region	NA	Surgical resection	Positive	Recurrence	Surgical resection 6xVAC	NED /167/160
4	180	M	Right scapula	NA	Surgical resection followed by second surgery for the residual	First: Positive Second: Negative	No		NED/180/176
5	7	M	Left lower extremity	NA	Surgical resection	Negative	No		NED /118/117
6	360	M	Right lower extremity	NA	Surgical resection	Negative	Recurrence	4xVAC, surgical resection	NED /118/115
7	180	F	Right lower extremity	NA	1xVA, 1xVAC	No surgery	Progression followed by local recurrence with distant metastasis (lung)	Surgical resection at progression 3xIE followed by surgical resection of both local and metastatic sites. 6xVTC after subsequent local recurrence.	NED /90/65
8	56	M	Chest wall	NA	Surgical resection	Positive	Recurrence	3xVA, surgical resection	NED/82/78
9	120	M	Left upper extremity	NTRK1-LMNA	6xVA	No surgery	Progression	Larotrectinib followed by surgical resection. Larotrectinib followed by surgical resection after local recurrence.	AWD/40
10	180	F	Right lower extremity	ETV6-NTRK3	4xVAC	No surgery	Progression	Surgical resection followed by larotrectinib, amputation after further local progression	NED/56/32
11	120	M	Right lower extremity		Chemotherapy followed by surgical resection*	Negative	No		NED/25/20
12	60	F	Left upper extremity	ETV6-NTRK3	2xVAC	No surgery	No	Larotrectinib	AWD/7

\* Chemotherapy information is not available  
X: Course F: Female, M: Male, VA: Vincristine, actinomycin-D, VAC: Vincristine, actinomycin-D, cyclophosphamide, IE: Ifosfamide, etoposide, VTC: vincristine, topotecan, cyclophosphamide, FU: follow-up, NA: not available, NED: no evidence of disease, AWD: Alive with disease

after the first surgery, respectively. The one with the recurrent tumor in the thoracic region received three courses of VA with weekly V, had a partial response and the tumor was totally resected with negative surgical margins and is under follow-up with no evidence of disease. The patient with a recurrent tumor in the cervical region was reoperated, had positive margins, he received six courses of VAC chemotherapy and is under follow-up with NED.

Seven patients were treated with neoadjuvant chemotherapy, two of these had complete response, surgery was not performed, and both are with no evidence of disease for a follow-up of 206+ and 155+ months. Of the seven patients treated with neoadjuvant chemotherapy, two developed veno-occlusive disease (VOD). One of them had a severe VOD after the first course of VAC, was in the ICU for 4 weeks and recovered. Treatment was continued with VA, starting with 50% doses and gradually increasing the dose.

One of the patients with the thigh as primary site was treated with neoadjuvant chemotherapy, had local progression after two courses of chemotherapy (VAC) and surgical resection was performed with negative surgical margins. Local recurrence developed in the third month after surgery and surgical resection was performed for the second time with negative surgical margins. Two months after the second surgical resection, local recurrence with lung metastasis developed. The patient was administered three courses of second line chemotherapy (ifosfamide and etoposide), however there was no response to chemotherapy. Both the local tumor and the lung metastasis were totally resected. Histopathological examination of the lung excision material revealed a hyalinized nodule considered as fibrosis after necrosis due to chemotherapy with a negative surgical margin and the tissue sample removed from the right thigh showed spindle cell fibroblastic proliferation, there was no viable tumor. The patient had a further local recurrence after four months. The tumor was resected with positive margins. She received six courses of third line chemotherapy consisting of vincristine, topotecan and cyclophosphamide (VTC). The patient is under follow-up with no evidence of disease (NED) (Table 1, patient 7).

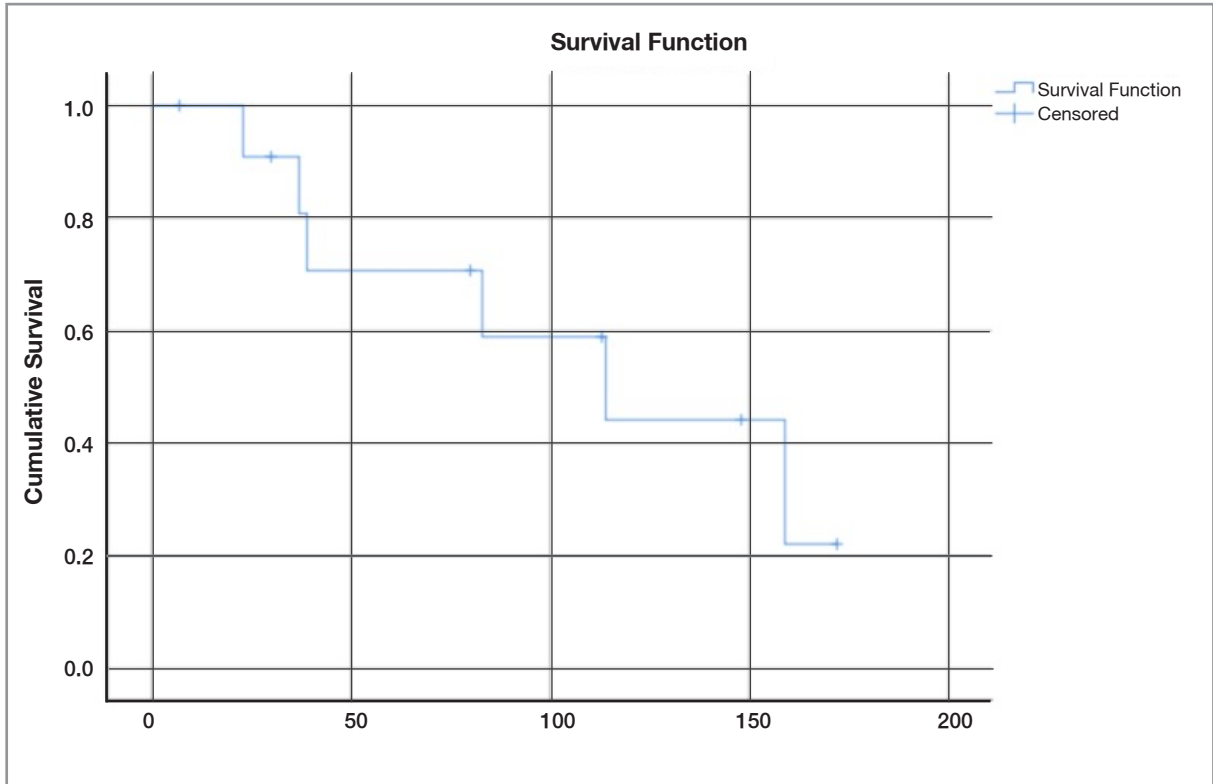
A patient with an unresectable tumor of the extremity received 6 courses of chemotherapy (VAC), had partial response and underwent a surgical resection with negative margins.

Oncogenic fusions of NTRK were detected in the other three patients who were also inoperable at diagnosis and initially treated with chemotherapy (VA). One of these patients developed local progression after 6 cycles of VA. A NTRK1-LMNA fusion was found in the tumor specimen. The patient was given larotrectinib (100 mg/m<sup>2</sup>/dose twice a day) for six months, the tumor regressed more than 90% in volume after which the tumor was totally resected. However, surgical margins were positive. Larotrectinib was continued for a total of 10 months. Seven months after larotrectinib was discontinued, local recurrence developed. Larotrectinib was restarted and followed by surgical resection one month later, surgical margins were positive. Larotrectinib was continued for two more months and was discontinued due to the problem to access to the drug. On magnetic resonance imaging (MRI) there was no mass. Local recurrence occurred once again six months later and larotrectinib was restarted (Table 1, patient 9).

A patient with an unresectable tumor of the sole, had a local progression after four courses of neoadjuvant chemotherapy (VAC). A surgical resection was done, surgical margins were positive. Due to the detection of the NTRK3-ETV6 fusion in the tumor, larotrectinib was initiated. After three months, progressive disease at the local site with regional lymph node involvement was observed. The family refused further treatment, the tumor progressed, she underwent an amputation and is alive with NED.

A one-month-old girl with an unresectable huge tumor on the left hand (Figure 1) received two courses of chemotherapy with a partial response, however it still is unresectable. She experienced VOD and was in the ICU for two weeks. A NTRK3-ETV6 fusion was detected by NGS, thus larotrectinib was started. After treatment with two courses of larotrectinib, the mass on the left hand regressed significantly.

At a median of 104-month (7-206) follow-up, all patients are alive. None of the patients underwent amputation. Nine of the twelve patients survived



**Figure 1.** Kaplan–Meier estimates presenting 5-year EFS % of infants with fibrosarcoma

disease-free for a median of 118 months (25-206). The 5-year OS and EFS of the patients were 100% and 70.7% respectively (Figure 1).

## DISCUSSION

Infantile fibrosarcoma (IFS) is a rare pediatric tumor with an estimated incidence of five per million infants, it is the most common soft tissue sarcoma in the first year of life.<sup>1,2</sup> IFS is usually located in deep soft tissues of the distal parts of the extremities and less frequently head, neck and trunk.<sup>16</sup> In a large series, the most common location was reported as the extremity with 66% of all cases, followed by trunk with 25%, the head and neck with 7%, the nonparameningeal and the orbital region with 2%.<sup>5</sup> In our study, the extremity was the most common primary site in our series (9 out of a total of 12 patients, 75%).

Metastasis is rare (1-13%) and the most common metastatic site is lungs. In our series, none had metastasis at diagnosis, one had lung metastasis at relapse.

Surgical treatment is the mainstay of treatment in localized tumors. However mutilating surgery shall be avoided. In patients with a total resection or surgery with microscopic residual disease, no further therapy is recommended.<sup>8</sup>

However, in our series, all cases with primary surgery with microscopic residual disease (positive surgical margins) recurred.

In patients where non-mutilating complete resection is not possible, neoadjuvant chemotherapy is recommended with the aim to achieve tumor shrinkage and a delayed complete surgery. Response to chemotherapy may be slow, at least three months should be waited for evaluation of tumor response in cases that have not progressed.<sup>3</sup>

Chemotherapy regimens consisting vincristine, dactinomycin, cyclophosphamide and doxorubicin have been shown to be effective. However, to avoid late cardiotoxicity, doxorubicin has not been widely used as first choice in these infants. Vincristine, dactinomycin, cyclophosphamide (VAC) had been frequently used in previous series, due to objective

responses and to reduce side effects, currently VA is recommended as initial treatment. Complete response to chemotherapy has been reported.<sup>17-19</sup>

In our series two patients had a complete response to chemotherapy and did not undergo any surgery and are long term survivors.

In EpSSG NRSTS 2005, 50 infants diagnosed with IFS were treated prospectively (from 2005 and 2012) with VA chemotherapy avoiding alkylating or anthracycline based chemotherapy to reduce therapy related long term side effects. The 3-year event-free survival and overall survival were reported as 84.0% and 94.0%, respectively.<sup>8</sup> Among a total of 172 European patients treated in Europe within the EpSSG/AIEOP/MMT (106 patients) and CWS (66 patients) studies between 1975 to 2017, 39% of the patients received surgery alone, 29% preoperative chemotherapy followed by delayed surgery, 11% surgery and adjuvant chemotherapy and 16% chemotherapy alone. In this study, 162 (94.1%) of 172 patients were alive at the end of the follow-up period, of which 40% were treated with surgery alone and 39% with a combination of surgery and chemotherapy. Among the survivors, 17% of patients treated with radiotherapy and mutilative surgery experienced functional disadvantages, there was one death due to toxicity and nine deaths due to refractory/relapsed disease.<sup>7</sup> Arndt et al. reported the risk of hepatopathy and death in children 36 months and younger treated with VAC with an incidence of 14% and 2.2% respectively.<sup>20</sup> Similarly, in our series, two patients who received the VAC chemotherapy regimen had severe VOD and were hospitalized in the intensive care unit for one and two months respectively. After the patient's general condition improved, treatment was continued by starting vincristine alone at a reduced dose, then actinomycin D at a low dose, and the dose of actinomycin D was gradually increased.

Infantile fibrosarcomas are highly cellular neoplasms of fibroblastic origin characterized by a quite uniform population of immature fibroblastic cells. Mitosis is frequent which is congruent with clinically rapid growth.<sup>21</sup> The histopathological features of IFS are similar to infantile fibromatosis or adult-type fibrosarcoma. IFS is thought to be driven by oncogenic activation of kinase signaling,

and in rare case due to complex activating mutations. Most cases harbor the ETV6–NTRK3 gene fusion resulting from t(12;15)(p13;q25), although rare cases involving other partners such as EML4–NTRK3 have been reported. We have had the opportunity to do molecular investigation for NTRK fusions recently and have detected NTRK fusions in all three patients tested. These gene fusions have been useful as a diagnostic tool in IFS also, as they are not found in adult-type fibrosarcoma, infantile fibromatosis, and myofibromatosis as well as other histologically similar spindle cell neoplasms. The expression of the ETV6–NTRK3 gene fusion and related fusions have also led to the development of targeted therapies.<sup>13,22,23</sup>

Recently developed targeted drugs have the ability to inhibit TRK activity including larotrectinib, repotrectinib, entrectinib, crizotinib, selitrectinib, lestaartinib and others.

Larotrectinib is FDA- and EMA-approved for the treatment of adult and pediatric patients (no lower age limit restriction) with solid tumors that display an NTRK fusion, who have a disease that is locally advanced, metastatic or where surgical resection is likely to result in severe morbidity, and who have no satisfactory treatment options.<sup>24</sup> In studies evaluating 28 patients with IFS, the overall tumor response rate was reported as 96% (82–100).<sup>9,25-27</sup>

Larotrectinib is not yet available in our country. We obtained it as compassionate use for two patients who progressed under conventional chemotherapy, one obtained a response that allowed a delayed complete surgical resection, however the other patient progressed under larotrectinib treatment. Another patient was approved for larotrectinib as compassionate use and will start as soon as the drug is obtained.

Investigational, newer generation TRKI such as entrectinib, selitrectinib, repotrectinib may be considered for patients who progress on prior TRKI.<sup>10,28-31</sup> However, they are not available in our setting.

The median duration of conventional chemotherapy in European cases with localized disease is 4 to 6 months. For initially unresectable tumors, the optimal duration of larotrectinib drug administration has not been defined and could last from 4 months



to more than 1 year.<sup>1,2,4,14-16,25</sup> It is nevertheless proposed to stop larotrectinib after a complete surgery of the primary has been performed in localized tumors.<sup>14</sup> However, in our patient with an objective response to larotrectinib and complete surgery, there was local recurrence and a response was further attained after the start of larotrectinib. It is not yet known for how long larotrectinib therapy should be continued in case of a complete clinical and radiological response of the tumor without surgery. The results of the attempts to discontinue therapy in these situations are not yet available.

In conclusion; infantile fibrosarcomas may show various clinical courses. Although surgical resection is the mainstay of treatment, it is not always possible to perform a non-mutilating surgery with a negative surgical margin safely. Both favorable responses can be obtained and surgery can be carried out more safely after chemotherapy first. Recently, molecular changes defined on tumor tissue have started to play important role in treatment by enabling targeted therapy. With the use of larotrectinib, it is also possible to avoid the undesirable side effects of conventional chemotherapy, but there is no consensus on the duration of treatment and therefore more studies are needed.

## REFERENCES

- Linabery AM, Ross JA. Childhood and adolescent cancer survival in the US by race and ethnicity for the diagnostic period 1975-1999. *Cancer* 113: 2575-2596, 2008.
- Sultan I, Casanova M, Al-Jumaily U, et al. Soft tissue sarcomas in the first year of life. *Eur J Cancer* 46(13): 2449-2456, 2010.
- Sparber-Sauer M, Vokuhl C, Seitz G, et al. The impact of local control in the treatment of children with advanced infantile and adult-type fibrosarcoma: Experience of the cooperative weichteilsarkom studien-gruppe (CWS). *J Pediatr Surg* 55: 1740-1747, 2020.
- Cecchetto G, Carli M, Alaggio R, et al. Fibrosarcoma in pediatric patients: results of the Italian Cooperative Group studies (1979-1995). *J Surg Oncol* 78: 225-31, 2001.
- Orbach D, Rey A, Cecchetto G, et al. Infantile fibrosarcoma: management based on the European experience. *J Clin Oncol* 28: 318-23, 2010.
- Soule EH, Pritchard DJ. Fibrosarcoma in infants and children: a review of 110 cases. *Cancer* 40: 1711-21, 1977.
- Orbach D, Sparber-Sauer M, Laetsch TW, et al. Spotlight on the treatment of infantile fibrosarcoma in the era of neurotrophic tropomyosin receptor kinase inhibitors: International consensus and remaining controversies. *Eur J Cancer* 137:183-192, 2020.
- Orbach D, Brennan B, De Paoli A, et al. Conservative strategy in infantile fibrosarcoma is possible: The European paediatric Soft tissue sarcoma Study Group experience. *Eur J Cancer* 57:1-9, 2016.
- Hong DS, DuBois SG, Kummar S, et al. Larotrectinib in patients with TRK fusion-positive solid tumours: a pooled analysis of three phase 1/2 clinical trials. *Lancet Oncol* 21: 531-540, 2020.
- Liu D, Offin M, Harnicar S, et al. Entrectinib: an orally available, selective tyrosine kinase inhibitor for the treatment of NTRK, ROS1, and ALK fusion-positive solid tumors. *Ther Clin Risk Manag* 14: 1247-1252, 2018.
- Bielack SS, Cox MC, Nathrath M, et al. Rapid, complete and sustained tumour response to the TRK inhibitor larotrectinib in an infant with recurrent, chemotherapy-refractory infantile fibrosarcoma carrying the characteristic ETV6-NTRK3 gene fusion. *Ann Oncol* 30 (Suppl\_8):viii31-viii35, 2019.
- Bender J, Anderson B, Bloom DA, et al. Refractory and metastatic infantile fibrosarcoma harboring LMNA-NTRK1 fusion shows complete and durable response to crizotinib. *Cold Spring Harb Mol Case Stud* 5: a 003376, 2019.
- Knezevich SR, McFadden DE, Tao W, et al. A novel ETV6-NTRK3 gene fusion in congenital fibrosarcoma. *Nat Genet* 18: 184-187, 1998.
- Bourgeois JM, Knezevich SR, Mathers JA, Sorensen PH. Molecular detection of the ETV6-NTRK3 gene fusion differentiates congenital fibrosarcoma from other childhood spindle cell tumors. *Am J Surg Pathol* 24: 937-946, 2000.
- Argani P, Fritsch M, Kadkol SS, et al. Detection of the ETV6-NTRK3 chimeric RNA of infantile fibrosarcoma/cellular congenital mesoblastic nephroma in paraffin-embedded tissue: application to challenging pediatric renal stromal tumors. *Mod Pathol* 13: 29-36, 2000.
- Ferrari A, Bisogno G, Schneider DT. EXPeRT: The European Cooperative Study Group for Pediatric Rare Tumors. In: Schneider DT, Brecht IB, Olson TA, Ferrari A, eds. *Rare Tumors in Children and Adolescents*. Cham, Springer International, 2nd Ed, 2022: 49-54.
- Surico G, Muggeo P, Daniele RM, et al. Chemotherapy alone for the treatment of congenital fibrosarcoma: is surgery always needed? *Med Pediatr Oncol* 40: 268-270, 2003.
- Grier HE, Perez-Atayde AR, Weinstein HJ. Chemotherapy for inoperable infantile fibrosarcoma. *Cancer* 56: 1507-1510, 1985.
- Ninane J, Gosseye S, Panteon E, et al. Congenital fibrosarcoma. Preoperative chemotherapy and conservative surgery. *Cancer* 58: 1400-1406, 1986.

20. Arndt C, Hawkins D, Anderson JR, et al. Age is a risk factor for chemotherapy-induced hepatopathy with vincristine, dactinomycin, and cyclophosphamide. *J Clin Oncol* 22: 1894-901, 2004.
21. Ferguson WS. Advances in the adjuvant treatment of infantile fibrosarcoma. *Expert Rev Anticancer Ther* 3: 185-191, 2003.
22. Shulman DS, DuBois SG. The evolving diagnostic and treatment landscape of NTRK-fusion-driven pediatric cancers. *Paediatr Drugs* 22: 189-197, 2020.
23. Lannon CL, Sorensen PH. ETV6-NTRK3: A chimeric protein tyrosine kinase with transformation activity in multiple cell lines. *Semin Cancer Biol* 15: 215-223, 2005.
24. Doebele RC, Davis LE, Vaishnavi A, et al. An Oncogenic NTRK Fusion in a Patient with Soft-Tissue Sarcoma with Response to the Tropomyosin-Related Kinase Inhibitor LOXO-101. *Cancer Discov* 5: 1049-1057, 2015.
25. DuBois SG, Laetsch TW, Federman N, et al. The use of neoadjuvant larotrectinib in the management of children with locally advanced TRK fusion sarcomas. *Cancer* 124: 4241-4247, 2018.
26. Laetsch TW, DuBois SG, Mascarenhas L, et al. Larotrectinib for paediatric solid tumours harbouring NTRK gene fusions: phase 1 results from a multicentre, open-label, phase 1/2 study. *Lancet Oncol* 19: 705-714, 2018.
27. Drilon A, Laetsch TW, Kummar S, et al. Efficacy of Larotrectinib in TRK Fusion-Positive Cancers in Adults and Children. *N Engl J Med* 378: 731-739, 2018.
28. Rolfo C, Ruiz R, Giovannetti E, et al. Entrectinib: a potent new TRK, ROS1, and ALK inhibitor. *Expert Opin Investig Drugs* 24: 1493-1500, 2015.
29. Hemming ML, Nathenson MJ, Lin JR, et al. Response and mechanisms of resistance to larotrectinib and selitrectinib in metastatic undifferentiated sarcoma harboring oncogenic fusion of NTRK1. *JCO Precis Oncol* 4: 79-90, 2020.
30. Hyman D, Kummar S, Farago A, et al. Abstract CT127: Phase I and expanded access experience of LOXO-195 (BAY 2731954), a selective next-generation TRK inhibitor (TRKi). *Cancer Research* 79 (13\_Supplement): CT127-CT127, 2019.
31. Drilon A, Ou SI, Cho BC, et al. Repotrectinib (TPX-0005) Is a Next-Generation ROS1/TRK/ALK Inhibitor That Potently Inhibits ROS1/TRK/ALK Solvent-Front Mutations. *Cancer Discov* 8: 1227-1236, 2018.

**Correspondence:**

**Dr. Rejin KEBUDI**

Istanbul Universitesi,  
Onkoloji Enstitüsü  
Pediatrik Hematoloji-Onkoloji Bolumu  
Capa  
ISTANBUL / TURKIYE

Tel: (+90-532) 445 90 38  
e-mail: rejinkebudi@yahoo.com

**ORCID:**

Ulku Miray Yildirim	0000-0003-0585-5123
Rejin Kebudi	0000-0003-4344-8174
Fikret Asarcikli	0000-0002-2879-6827
Banu Oflaz Sozmen	0000-0001-7212-7041
Ekrem Unal	0000-0002-2691-4826
Alper Ozcan	0000-0002-6100-1205
Bulent Zulfikar	0000-0002-7586-6939