

# A Comparison of Magnetic Resonance and Computed Tomography Imaging Based Target-Volume Definition and Interfraction Variations of Treatment Planning Parameters (D90 HR-CTV, D2cc for OARs) During Image Guided Adaptive Brachytherapy for Cervical Cancer

Hazim Orhan KIZILKAYA<sup>1</sup>, Ayse Kutluhan DOGAN<sup>1</sup>, Zedef DAG<sup>2</sup>, Halime Can TURAN<sup>3</sup>,  
Donay Unluer AKSAN<sup>4</sup>, Nazmiye Deniz ARSLAN<sup>2</sup>

<sup>1</sup> Health Sciences University, Sisli Hamidiye Etfal Training and Research Hospital,  
Department of Radiation Oncology, Istanbul

<sup>2</sup> Health Sciences University, Yedikule Chest Diseases and Thoracic Surgery Training  
and Research Hospital, Department of Radiation Oncology, Istanbul

<sup>3</sup> Health Sciences University, Sisli Hamidiye Etfal Training and Research Hospital,  
Department of Radiation Oncology, Medical Physics, Istanbul

<sup>4</sup> Health Sciences University, Samsun Training and Research Hospital,  
Department of Radiation Oncology, Samsun, TURKEY

## ABSTRACT

The aim of this study is to compare computed tomography (CT) and magnetic resonance imaging (MRI) based high-risk clinical target volume (HR-CTV) contours in brachytherapy (BT) for cervical cancer in order to identify patients who may benefit most from MRI-based planning. We also analyzed interfraction variations of the organ at risk (OAR) affects the given doses. Twenty patients who had a pretreatment diagnostic MRI were included. We delineated the HR-CTV and OARs on the CT- and MRI- based scans independently for each patient. Dose-volume parameters D90 HR-CTV and D2cc OARs in CT and MRI plannings were determined and compared; the effect of time on the natural mobility was analyzed. The mean CT and MRI HR-CTV were  $28.4 \pm 11 \text{ cm}^3$ ;  $19.0 \pm 8.1$ , ( $p < 0.001$ ), respectively. The mean EQD2 of CT and MRI HR-CTV were  $93.2 \pm 1.1 \text{ Gy}$ ;  $92.7 \pm 0.6 \text{ Gy}$ , ( $p < 0.041$ ). The mean D2cc of the rectum, bladder, and sigmoid in CT-based plans were higher (17%, 13.3% and 22.8%, respectively) than MRI-based plannings and significant differences were found in patients between the D2cc of rectum ( $p < 0.001$ ) and sigmoid ( $p < 0.001$ ). Furthermore, the interfraction volume variations and mean EQD2 doses for all OARs and HR-CTV were statistically insignificant in both image-guided plannings. The use of MRI-based BT for target localization in cervical cancer provides an improved accuracy and precision of the tumor volume as well as a similar dose coverage to the HR-CTV and better minimize the D2cc values of OARs, when it is compared with CT-based planning.

**Keywords:** Cervical cancer, Image-guided brachytherapy, MRI- guided brachytherapy, CT- guided brachytherapy

**ORCID:** Hazim Orhan Kizilkaya: 0000-0001-6946-7539  
Halime Can Turan: 0000-0002-8595-2929  
Nazmiye Deniz Arslan: 0000-0003-0080-2284

Ayşe Kutluhan Dogan: 0000-0002-8595-2929  
Donay Unluer Aksan: 0000-0003-0858-4015

Zedef Dag: 0000-0002-8595-2929

## ABSTRACT

### Serviks Kanserinde BT ve MR Görüntü Eşliğinde Uygulanan Adaptif Brakiterapi de Hedef Volüm Tanımı ve Dozimetrik Parametrelerin (D90 HR-CTV, D2cc OAR) Fraksiyonlar Arası Değişikliklerinin Karşılaştırılması

Bu çalışmamızda inoperabil serviks kanserli hastaların brakiterapisinde 3B görüntü eşliğinde BT-MR planlarında HR-CTV, GTV ve RO (rektum, mesane ve sigmoid) doz-volüm parametrelerini karşılaştırmayı amaçladık. Nisan 2017- Aralık 2017 tarihleri arasında, inoperabil serviks kanseri tanısı ile 50,4 Gy EBRT ile birlikte haftalık 40 mg/m<sup>2</sup> sisplatin uygulanan 20 hastaya, Nucletron Micro Selectron HDR afterloading cihazı ile haftada iki kez, her fraksiyonda genel anestezi altında tandem / ring aplikatörleri uygulandı. Her bir hastaya 5 fr x 6Gy'lik doz reçete edildi. Yirmi hastanın 3 boyutlu brakiterapisinde, HR-CTV, GTV ve RO volümleri her hasta için BT ve MR görüntülerinde ayrı ayrı konturlandı. Her iki planlama yönteminin doz-volüm parametreleri (D90 HR-CTV ve D2cc RO) istatistiksel olarak karşılaştırıldı. Ayrıca fraksiyonlar arası organ volüm değişiklikleri ve etkileri analiz edildi. BULGULAR: Sırasıyla ortalama BT ve MR HR-CTV; 28.4 ±11 cm<sup>3</sup>; 19.0±8.1' idi (p< 0.001). BT ve MR HR-CTV ortalama EQD2 değerleri; 93.2 ±1.1Gy; 92.7±0.6 Gy olarak bulundu (p< 0.041). Rektum, mesane ve sigmoid ortalama D2cc değerleri, BT planlamada (sırasıyla; %17, %13.3 ve %22.8) MR planlamaya kıyasla daha yüksek bulunmuştur. Bu doz yüksekliği rektum ve sigmoid için istatistiksel olarak anlamlıdır (p< 0.001). Ayrıca, fraksiyonlar arası organ volüm değişiklikleri ve HR-CTV ve OAR ortalama EQD2 değerleri her iki planlama yönteminde istatistiksel olarak anlamlı bulunmadı. MR eşliğinde brakiterapi planlamada hedef volümün en doğru şekilde belirlenebildiği, HR-CTV nin BT-planlamaya kıyasla daha küçük olduğu, böylelikle riskli organ dozlarının da daha düşük olabildiği gösterilmiştir.

**Anahtar Kelimeler:** Serviks kanseri, 3-boyutlu brakiterapi, BT-eşliğinde brakiterapi, MR-eşliğinde brakiterapi, Adaptif brakiterapi

## INTRODUCTION

Brachytherapy is a crucial component in the treatment of locally advanced cervical cancer.<sup>1,2</sup> During the last 20 years, image guided adaptive brachytherapy (IGABT), a high precision radiation technique has been developed through progress in afterloaders, applicators and computer software which enable the integration of 3D images such as MRI into treatment planning. This approach includes accurate delineation of tumor and targets and the organs at risk, as well as optimized 3D treatment planning based on dose-volume histograms. The addition of brachytherapy serves to boost the gross tumor and thus improves disease control and survival.<sup>3,4</sup>

In 2005 and 2006 the Group European de Curie-therapie-European Society for Therapeutic Radiology and Oncology (GEC ESTRO) working group published recommendations for contouring and reporting of 3D image-based treatment planning in cervical cancer BT.<sup>5,6</sup> These recommendations were developed to allow treatment comparison between centres with different traditions regarding applicators, dose rates and treatment schedules. Since then the number of centres that changed their treatment approach from point based to volume based treatment planning has been increasing rapidly, and improved target coverage and a reduction in OARs dose, have been published for different applicator types as institutional reports.<sup>7-11</sup>

According to previous studies, MRI with image-guided adaptive cervical cancer BT is still gold standard. MRI is superior to CT for soft tissue visualization. Whenever access proves difficult, BT planning with CT provides useful information, such as applicator position or delineating the organ at risk, which is comparable with MRI.<sup>12</sup> When MRI is not available CT is an acceptable alternative not exactly preferred. In this prospective study we compared the impacts of the target delineation accuracies obtained using imaging with CT only and MRI only on the dose distributions in cervical cancer BT planning. Furthermore, we analyzed interfraction dose variations in the OAR and the regression of gross tumor volume in our patient population.

## PATIENTS and METHODS

### Patient selection

This study was approved by institutional review board (04.2019). Twenty consecutive patients with cervical cancer, International Federation of Gynecology and Obstetrics (FIGO) Stage IIB–IIIB, were treated with combined external beam radiotherapy (EBRT), weekly concomitant cisplatin (40 mg/m<sup>2</sup>) and CT guided HDR BT, from April 2017 to December 2017. Initial locoregional staging involved a clinical examination, abdominal and pelvic MRI, F-18 FDG PET-CT, and biopsy-proven cervical

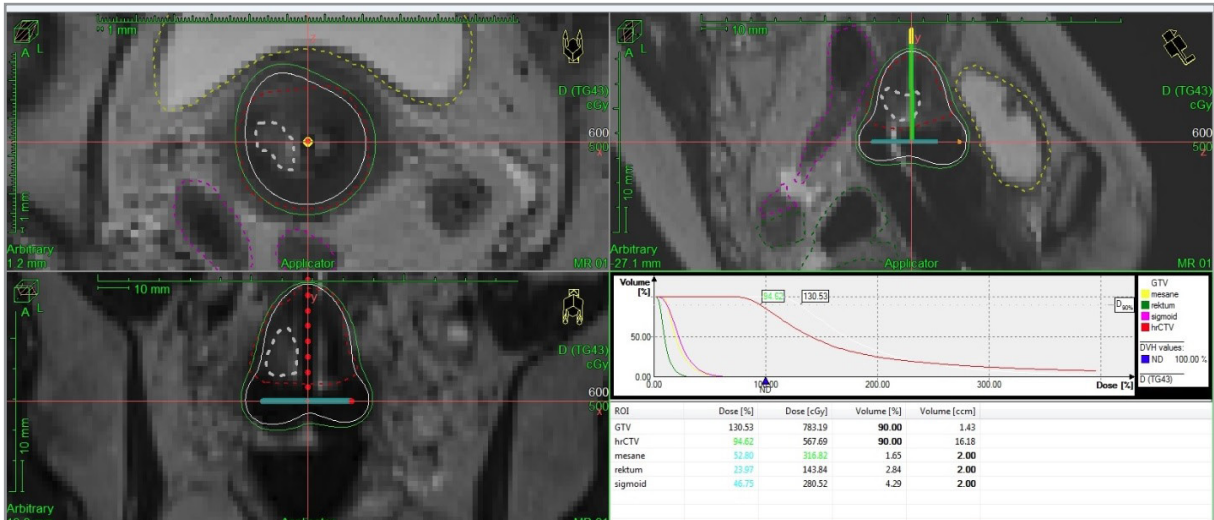


Figure 1. The first fraction of patient with gross residual tumor on Ct-based brachytherapy planning

cancer in all patients. Four patients were excluded due to poor MR images.

EBRT consisted of 3D conformal or intensity modulated pelvic radiation therapy to a physical dose of 50.4 Gy delivered in 1.8 Gy fractions. 3D CT guided HDR BT was initiated after completion of EBRT. Intracavitary radiation therapy, using a CT-MR compatible tandem/ring applicators (Nucletron, Veenendaal, The Netherlands), was performed for each treatment application. All patients followed the bladder filling protocol with 50 ml saline with nonionic contrast dye before the MRI and CT scans.

### Image Acquisition

The first BT fraction consisted of inserting the applicator under general anesthesia in the operating room, after approximately 30 minutes later, patients with an applicator (without any dummy markers inside the applicators) underwent T2- weighted MR imaging, with a 3 mm slice thickness using a 1.5-Tesla MRI scanner (Magnetom Avanto, Siemens, Erlangen, Germany) and CT imaging with a 3mm slice thickness (Toshiba Alexion,16-slice, Japan) for BT planning. The images were exported to BT planning system (TPS) ( Oncentra version 4.5.3.30, Nucletron, Vendaal, Netherlands).

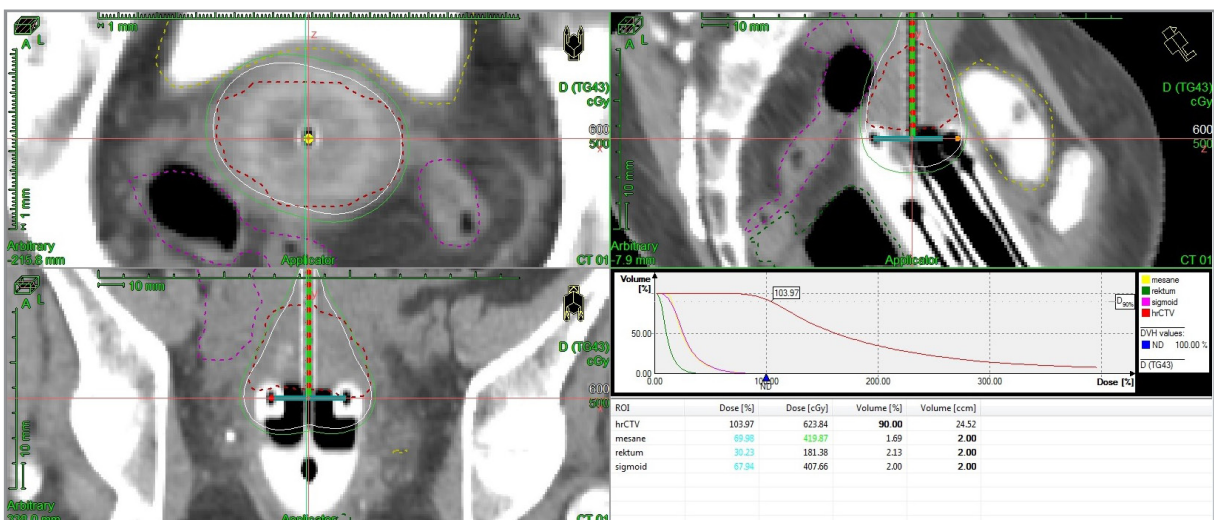
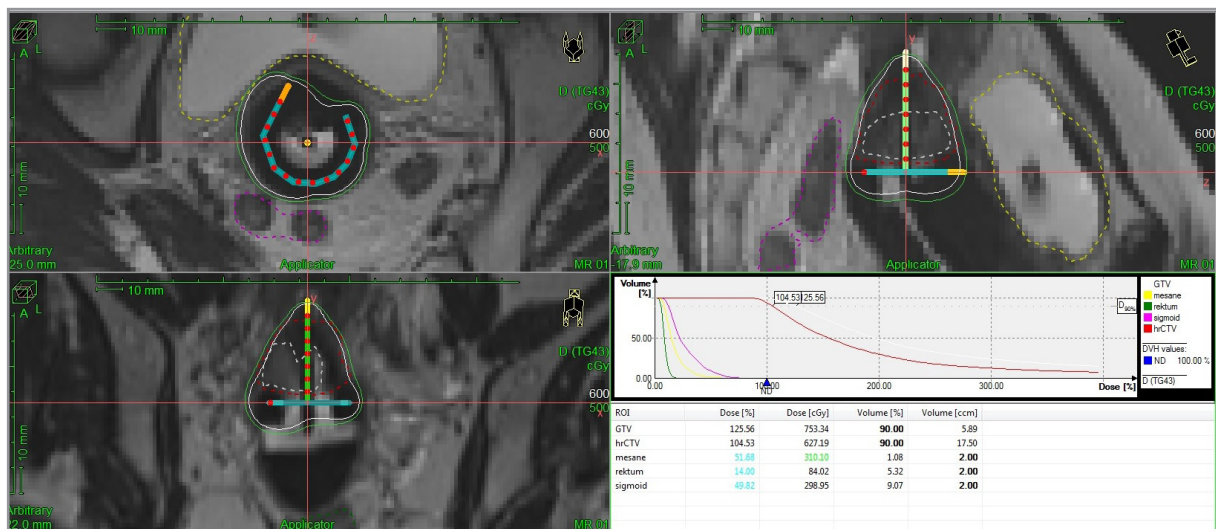


Figure 2. The fifth fraction of patient with gross residual tumor on Ct-based brachytherapy planning



**Figure 3.** The first fraction of patient with gross residual tumor on MRI-based brachytherapy planning.

### Contouring, Planning and Dose Parameters

All contours and plans were performed on CT and MRI based images in the trial (Figure 1-2). The physician delineated the high-risk clinical target volume, and the OARs (i.e. rectum, bladder, and sigmoid) according to GEC-ESTRO recommendations, using firstly CT imaging and then independently, the MRI. The CT HR-CTV was contoured according to pre-EBRT and pre-BT MRI findings by contouring investigator (A.K.D). The MRI GTV was determined to be a tumor in the BT fractions as represented by a high signal- intensity mass on pre-BT MRI in ten patients (Figure 3).

The D90 HR-CTV (minimum dose to 90% of the HR-CTV) and D2cc (minimum dose of the most exposed 2 cm<sup>3</sup> volume) of the OARs were calculated.<sup>6,8</sup> Physical doses were converted to EQD2 using the linear quadratic model with a/b= 10 Gy for HR-CTV and a/b= 3 Gy for OARs.<sup>13</sup> The planning objective for the HR-CTV was D90 ≥ 85 Gy EQD2 (total dose EBRT + BT). The constraints for the D2cc OARs were 90 Gy EQD2 for the bladder and 75 Gy EQD2 for rectum and sigmoid. During BT HDR treatment planning, differences in the position of OAR in relation to the target in both CT and MRI images were observed. Volumes in cubic centimeters were obtained for each HR-CTV and OARs contour, then, the interfractional dosimetric parameters were compared for both plans.

### Image Guided BT

All patients underwent 5 treatment fractions (twice in a week) with prescribed dose of 6 Gy to HR-CTV according to GEC-ESTRO recommendations<sup>5,6</sup> (D90 ≥ 85 Gy equivalent dose, a/β 10) image guided HDR BT. HDR BT was delivered using an Ir-192 source (10 Ci nominal activity) from Nucletron devices (Microselectron).

### Statistical Analyses

All statistical analyses were performed using SPSS software (Version 22.0; SPSS Inc., Chicago, IL) with a value of p < 0.05 considered to be significant. Descriptive statistics such as mean, median, minimum and maximum doses and volumes were calculated. Differences in contouring modalities were compared by mean values using paired T- test, Friedman test and Wilcoxon tests, as appropriate.

### RESULTS

A total of 80 BT applications were performed for all 16 patients included in the study. The median age of patients at the time of the treatment was 49.4 ± 13.8 years.

**Table 1.** Dosimetric comparison of volumes and doses between MRI-based and CT-based brachytherapy plannings

		Min-Max	Median	Mean±SD	p
Age		34-79	46	49.4±13.8	
HR-CTV	MRI	7.9-35.3	16.3	19.0±8.1	< 0.001*
	CT	12.8-62.8	27.3	28.4±11.0	
Bladder Volume	MRI	35-333	110.5	116.1±43.5	0.441*
	CT	50-332	114	118.7±33.6	
Rectum Volume	MRI	30-100	52	55.7±17.7	< 0.001*
	CT	29-150	65	68.6±24.0	
Sigmoid Volume	MRI	4-145	25.5	31.3±21.0	< 0.001#
	CT	15-163	46.5	55.8±33.7	
HR-CTV Dose	MRI	568-651	636	633.5±12.6	0.009*
	CT	600-689	643	638.9±18.7	
Bladder Dose	MRI	182-474	314	317.7±65.7	< 0.001*
	CT	164-492	392	375.7±68.5	
Rectum Dose	MRI	73-400	177	191.4±77.0	< 0.001*
	CT	75-436	236	240.7±86.5	
Sigmoid Dose	MRI	51-441	238	243.7±86.5	< 0.001#
	CT	106-455	335	322.2±77.1	

\*= Wilcoxon Test; #= Paired t Test

### Comparison of Magnetic Resonance and Computed Tomography Imaging Based Target and OARs Volume-Dose Definition

Optimization ensured that the CT or MR HR-CTV D90 was maximized while reducing doses to the organs at risk (OARs), the sigmoid, rectum and bladder as far as feasible. According to 160 treatment planning (both MRI and CT) results; the mean CT HR-CTV was  $28.4 \pm 11 \text{ cm}^3$ , and the mean MRI HR-CTV was  $19.0 \pm 8.1$ , with statistical significance ( $p < 0.001$ ). The mean EQD2 of CT HR-CTV was  $93.2 \pm 1.1 \text{ Gy}$ , and the mean EQD2 of MRI HR-CTV was  $92.7 \pm 0.6 \text{ Gy}$ , with statistical significance ( $p < 0.041$ ). The mean volumes of CT-based rectum and sigmoid were significantly higher than MRI volumes ( $p < 0.05$ ). There was no significant difference between MRI and CT bladder volume. The mean value of D2cc of the bladder, rectum and sigmoid in CT- and MRI- based plannings were  $72.1 \pm 8.3$ ,  $69.7 \pm 5.5 \text{ Gy}$ ;  $63.2 \pm 5.5$ ,  $59.4 \pm 4.9 \text{ Gy}$ ;  $70.2 \pm 5.9$ ,  $63.5 \pm 5 \text{ Gy}$ , respectively. The mean value of D2cc of the rectum, bladder, and sigmoid in CT-based plannings were higher (17%, 13.3% and 22.8%, respectively) than MRI-based plannings and statistically significant differences were found in patients between the

D2cc of rectum ( $p < 0.001$ ) and sigmoid ( $p < 0.001$ ) in MRI- and CT-based plannings (Table 1).

### GTV-MRI

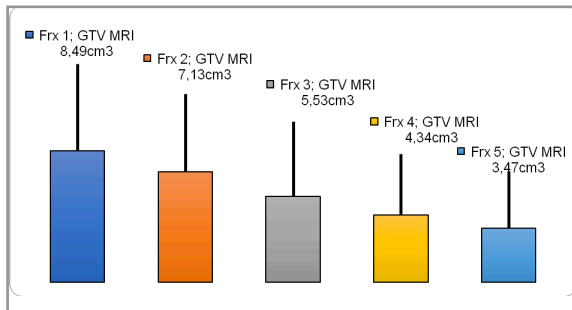
Among these patients, 10 patients had residual tumor confined to the cervix on pre-BT MRI. Therefore, the volume of gross tumor contoured were recorded for every insertion on MRI-based plannings. The mean value of the GTV was the highest for the first application ( $8,49 \pm 5.61 \text{ cm}^3$ ) and the lowest for the fifth application ( $3.47 \pm 3.70 \text{ cm}^3$ ) ( $p < 0.001$ ) (Table 2). The maximum decrease in gross tumor volume during the BT was between 2. and 3. fractions ( $1.6 \text{ cm}^3$ ,  $p < 0.024$ ) (Figure 5).

### Interfraction Variations of MRI- and CT-based Treatment Planning Parameters

As is evident from the p values shown in Table 3 and Table 4, the interfraction volume variations and mean EQD2 doses for all OARs and HR-CTV were statistically insignificant in both CT and MR image guided plannings. The mean value of D2cc of the bladder was the lowest for the first applica-

**Table 2.** The mean volume for the MRI-GTV along with interfraction comparison P values

		Min-Max	Median	Mean±SD	p
GTV MRI	1.Frx	1.71-16.72	7.82	8.49±5.61	< 0.001
	2.Frx	0.77-16.05	6.31	7.13±5.04	
	3.Frx	0.93-12.89	3.93	5.53±4.85	
	4.Frx	0.45-11.18	2.95	4.34±3.96	
	5.Frx	0.38-10.91	1.69	3.47±3.70	



**Figure 5.** The mean volume for the MRI-GTV along with interfraction comparison

tion ( $3.08 \pm 0.8$  Gy) and the highest for the fifth application ( $3.2 \pm 0.7$  Gy) on MRI-based planning. The mean value of D2cc for rectum was the highest for the third application ( $2.07 \pm 0.9$  Gy) and the lowest for the fifth application ( $1.78 \pm 0.7$  Gy) on MRI-based planning. The mean value of D2cc for sigmoid was lowest for the third application ( $3.07 \pm 0.7$  Gy) and the highest for the fifth fraction ( $3.45 \pm 0.7$  Gy) and the mean values of EQD2 for bladder and rectum were  $82.74 \pm 10.05$  Gy,  $69.57 \pm 6.4$  Gy on MRI-based planning, respectively.

**DISCUSSION**

At present, MRI has been incorporated into brachytherapy for diagnosis and dosimetry because it provides superior definition of cervical tumors, their expansion, local involvement, and relationship with OARs. The new volume definition with MRI has allowed the concept of BT which is defined by American Brachytherapy Society (ABS) and GEC-ESTRO<sup>5,6,14,15</sup> with published several reports describing commissioning, reconstruction, and establishing MRI recommendations.<sup>5-9</sup>

BT for cervical cancer in Turkey is rapidly transitioning from 2D to 3D treatment planning and majority of institutes that perform 3D treatment planning primarily use CT in nowadays.<sup>16</sup> CT is the most commonly performed imaging modality for the 3D planning of BT, although the MRI is a gold standard for planning of BT in cervical cancer. CT allows for OAR delineation, but CT-based target contouring shows systematically wider contours than with MRI.<sup>18</sup> This uncertainty limits the degree of dose optimization, particularly in large tumors with parametrial invasion. Therefore, we conducted a study which is comparison of MRI and CT-based target volume definition and interfraction variations of treatment planning parameters (D90 HR-CTV, D2cc for OARs).

Regarding the difference in the target volume using CT and MRI for brachytherapy for cervical cancer, Swanick et al.<sup>19</sup> studied the HR-CTV volume using two image modalities, and showed that the mean HR-CTV volume obtained using CT ( $44.1 \text{ cm}^3$ ) was larger than that obtained using MRI ( $35.1 \text{ cm}^3$ ), with statistical significance ( $p < 0.0001$ ). Due to increased discrepancy in the HR-CTV volume obtained with MRI, they concluded that MRI -based BT planning should be considered for the use in patients with a higher body mass index and a tumor size of 5 cm or greater, with parametrial invasion. In our study, the HR-CTV volume obtained from CT-based planning was overestimated compared to the volumes acquired using MRI-based planning ( CT HR-CTV;  $28.4 \pm 11 \text{ cm}^3$ , MRI HR-CTV;  $19.0 \pm 8.1$ ,  $p < 0.001$ ). As a result, the HR-CTV doses obtained from CT-based planning were higher than those provided by the MR-based BT in almost every fraction (EQD2 of CT HR-CTV;  $93.2 \pm 1.1$  Gy, and EQD2 of MRI HR-CTV;  $92.7 \pm 0.6$  Gy,  $p < 0.041$ ). These outcomes are very similar to those in Nesvacil study<sup>20</sup>, and

**Table 3.** The mean volume for all the OARs and HR-CTVs in CT- and MRI-based plannings along with interfraction comparison P values

Volume		Min-Max	Median	Mean±SD	p
HR-CTV (MRI)	1.Fr	8-35.1	16.4	19.4±8.8	0.315
	2.Fr	8.4-34.5	18.2	19.5±8.1	
	3.Fr	7.9-35.3	15.8	19.0±8.4	
	4.Fr	8.2-35.0	17.8	18.9±8.3	
	5.Fr	9-34.95	16.78	18.2±7.9	
HR-CTV (CT)	1.Fr	12.8-47.6	25.7	27.9±10.0	0.578
	2.Fr	13.7-48.9	29.8	30.2±10.8	
	3.Fr	15.1-49.6	26.3	26.7±9.3	
	4.Fr	13.2-62.8	28.7	29.0±13.4	
	5.Fr	14.9-61.9	26.1	28.0±11.9	
Bladder (MRI)	1.Fr	35-333	106	124.4±65.6	0.447
	2.Fr	35-160	106	101.7±31.3	
	3.Fr	71-167	107	115.1±26.8	
	4.Fr	47-212	111	115.9±38.0	
	5.Fr	35-217	125	123.4±46.3	
Bladder (CT)	1.Fr	73-332	113.5	125.2±59.8	0.408
	2.Fr	55-155	113.5	109.3±22.3	
	3.Fr	80-152	112.5	115.6±19.8	
	4.Fr	79-147	118	119.3±17.8	
	5.Fr	50-190	121	123.9±31.4	
Rectum (MRI)	1.Fr	34-81	44	51.6±15.5	0.371
	2.Fr	31-100	56.5	60.8±23.5	
	3.Fr	40-86	54.5	56.1±13.9	
	4.Fr	30-99	52.5	56.2±18.6	
	5.Fr	30-92	48.5	53.8±16.2	
Rectum (CT)	1.Fr	39-103	56.2	60.2±18.3	0.420
	2.Fr	29-125	76	72.7±30.1	
	3.Fr	34-96	64.5	67.8±17.2	
	4.Fr	39-120	68.5	71.9±22.8	
	5.Fr	33-150	66.5	70.5±29.5	
Sigmoid (MRI)	1.Fr	11-54	26	29.3±13.4	0.349
	2.Fr	11-145	29	36.4±32.7	
	3.Fr	4-66	29	31.8±17.9	
	4.Fr	9-72	24	26.6±15.9	
	5.Fr	7-72	23	32.2±21.1	
Sigmoid (CT)	1.Fr	21-137	47	54.3±30.4	0.681
	2.Fr	15-163	48	59.8±42.9	
	3.Fr	16-145	44.5	51.9±31.3	
	4.Fr	23-153	46.5	53.4±	
	5.Fr	15-144	50	59.5±34.7	

**Table 4.** The mean value of D2cc for all the OARs and D90 HR-CTVs in CT- and MRI-based plannings along with interfraction comparison P values

Dose		Min-Max	Median	Mean±SD	p
HR-CTV (MRI)	1.Fr	606-651	632.5	633.4±12.1	0.655
	2.Fr	618-651	639	636.8±9.1	
	3.Fr	605-648	634.5	631.3±13.3	
	4.Fr	622-648	636	634.8±7.5	
	5.Fr	568-646	636	631.3±18.5	
HR-CTV (CT)	1.Fr	619-689	644	647.3±18.9	0.228
	2.Fr	603-659	643	635.6±16.4	
	3.Fr	600-665	639	637.1±17.4	
	4.Fr	602-678	642	638.5±20.0	
	5.Fr	600-668	643.5	636.3±20.0	
Bladder (MRI)	1.Fr	233-474	292	308.5±78.5	0.922
	2.Fr	237-405	315	318.8±48.8	
	3.Fr	192-448	303.5	317.9±65.7	
	4.Fr	182-406	327.5	317.4±70.7	
	5.Fr	213-434	331.5	322.0±68.9	
Bladder (CT)	1.Fr	275-492	373	375.7±64.0	0.441
	2.Fr	252-462	368	367.8±59.9	
	3.Fr	252-486	404	392.9±63.2	
	4.Fr	164-463	384.5	360.4±93.2	
	5.Fr	238-467	385	379.9±58.9	
Rectum (MRI)	1.Fr	84-285	202	186.1±59.8	0.442
	2.Fr	107-353	168	195.4±77.4	
	3.Fr	93-350	225.5	207.8±89.3	
	4.Fr	73-400	162.5	188.9±84.0	
	5.Fr	77-359	146	178.8±77.4	
Rectum (CT)	1.Fr	120-429	246	237.6±70.3	0.529
	2.Fr	168-383	237.5	252.7±67.8	
	3.Fr	92-412	216.5	239.6±98.1	
	4.Fr	75-436	272.5	253.6±109.8	
	5.Fr	92-427	215	218.5±83.0	
Sigmoid (MRI)	1.Fr	112-352	238	237.9±77.3	0.428
	2.Fr	112-441	263	262.7±98.6	
	3.Fr	51-441	233.5	246.8±94.2	
	4.Fr	56-362	231	227.4±78.3	
	5.Fr	52-371	255	248.0±88.2	
Sigmoid (CT)	1.Fr	182-442	322	323.9±82.4	0.353
	2.Fr	106-450	326.5	319.3±96.5	
	3.Fr	132-394	311.5	307.1±68.6	
	4.Fr	194-433	340	321.8±73.0	
	5.Fr	217-455	354	345.3±68.3	



they suggested that the overestimations on the CT images can be overcome by using MRI to guide contouring on the fractions of the CT images.

Choong et al.<sup>21</sup> analyzed 76 cervical cancer patients who had been divided into 49 cases with CT- and MRI-guided brachytherapy and 27 cases with MRI-guided only brachytherapy. The results showed no statistically significant differences in the clinical outcomes or dosimetric analyses of the two approaches. Wang et al.<sup>22</sup> reviewed 13 clinical studies comprising a total of 465 patients to evaluate the accuracy of two image modalities for the brachytherapy of cervical cancer. Ten studies compared CT to MRI, while the other three compared MRI1st/CT to MRI-based imaging. They found that, compared to MRI, the HR-CTV width had been overestimated, while the height might have been underestimated when using CT. The dosimetric analyses for the HR-CTV were also lower for the CT-only approach compared with at least one fraction of the MRI-based brachytherapy. In contrast to that study, we found out that D90 to the CT HR-CTV was higher than MRI HR-CTV. In our study, optimization ensured that the CT or MR HR-CTV D90 was maximized while reducing doses to the organs at risk, as far as feasible. Although the CT HR-CTV was larger, we still had good dose coverage and higher D90 doses to the CT HR-CTV, while achieving OAR doses at accepted limits.

As to fraction-by-fraction comparisons between MRI and CT-based plannings, there was a significant overestimation of the OARs volumes, HR-CTV and dosimetric parameters on the CT based BT planning. Furthermore, this study demonstrated that there were insignificant differences in the two BT plannings for the interfractional variations of volumes and doses of OARs and HR-CTV. It can be explained the relatively small sample size as well as due to the fact that since each fraction was individually planned all attempts were made to keep the OARs doses below prescribed limits. And also, good preparation before every each BT fraction (filling bladder, emptying rectum with enema) has the key role to keep the similar volumes and OARs doses below limits. In addition, although tumor size shrunk well last BT fraction, it did not change the HR-CTV because of all residual tumor was con-

finied to the cervix on pre-BT MRI. For that reason, it is important to make individually plan each BT fraction to avoid higher doses to the OARs.

A current limitation on the spread of MRI-guided brachytherapy in cervical cancer is difficulty in accessing MRI and increasing costs of additional imaging. The importance of performing repeated MRI in BT depends on tumor size and the timing of brachytherapy.<sup>23-25</sup> As a result of this study, the maximum decrease in GTV during the BT was between 2. and 3. fractions. Therefore, such scenarios in BT may include MRI without the applicator in place combined with CT, or MRI for the first and third BT fractions combined with CT for subsequent fractions.

One strength of our study is that all contours were generated systematically by one investigator and then reviewed by at least one additional investigator with expertise in BT. The study was further strengthened by the availability of pretreatment diagnostic MRI scans for all patients, which allowed us to identify disease characteristics at diagnosis that predicted differences in HR-CTV volumes, and this in turn allows for early identification of patients who may require MRI at the time of BT.

Our study's limitation is including small number of patients, and individually plan each BT fraction to avoid higher doses to the OARs. With the amount of data and subsequent analyses presented in this work, we are not in a position to attribute any specific parameter(s) for observed interfraction variations in D2cc values of the OARs.

## Conclusion

The use of MRI-based BT for target localization in cervical cancer provides an improved accuracy and precision of the tumor volume as well as a similar dose coverage to the HR-CTV and minimize the D2cc values of OARs, when it is compared with CT-based planning. Future efforts in cervical cancer should be directed toward dissemination of MRI guidance through focused training and establishment of high quality treatment in centers with multidisciplinary expertise and sufficient patient load.

REFERENCES

1. Tanderup K, Eifel PJ, Yashar CM, et al. Curative radiation therapy for locally advanced cervical cancer: brachytherapy is NOT optional. *Int J Radiat Oncol Biol Phys* 88: 537-539, 2014.
2. Tanderup K, Fokdal LU, Sturdza A, et al. Effect of tumor dose, volume and overall treatment time on local control after radiochemotherapy including MRI guided brachytherapy of locally advanced cervical cancer. *Radiother Oncol* 120: 441-446, 2016.
3. Lanciano RM, Won M, Coia LR, Hanks GE. Pretreatment and treatment factors associated with improved outcome in squamous cell carcinoma of the uterine cervix: A final report of the 1973 and 1978 patterns of care studies. *Int J Radiat Oncol Biol Phys* 20: 667-676, 1991.
4. Logsdon MD, Eifel PJ. Figo IIIB squamous cell carcinoma of the cervix: An analysis of prognostic factors emphasizing the balance between external beam and intracavitary radiation therapy. *Int J Radiat Oncol Biol Phys* 43: 763-775, 1999.
5. Haie-Meder C, Pötter R, Van Limbergen E, et al. Recommendations from Gynaecological (GYN) GEC-ESTRO Working Group (I): concepts and terms in 3D image based 3D treatment planning in cervix cancer brachytherapy with emphasis on MRI assessment of GTV and CTV. *Radiother Oncol* 74: 235-245, 2005.
6. Pötter R, Haie-Meder C, Van Limbergen E, et al. Recommendations from Gynaecological (GYN) GEC-ESTRO Working Group (II): concepts and terms in 3D image based 3D treatment planning in cervix cancer brachytherapy-3D dose volume parameters and aspects of 3D image-based anatomy, radiation physics, radiobiology. *Radiother Oncol* 78: 67-77, 2006.
7. Kirisits C, Potter R, Lang S, et al. Dose and volume parameters for MRI-based treatment planning in intracavitary brachytherapy for cervical cancer. *Int J Radiat Oncol Biol Phys* 62: 901-911, 2005.
8. De Brabandere M, Mousa AG, Nulens A, et al. Potential of dose optimisation in MRI-based PDR brachytherapy of cervix carcinoma. *Radiother Oncol* 88: 217-226, 2008.
9. Lindegaard JC, Tanderup K, Nielsen SK, et al. MRI-guided 3D optimization significantly improves DVH parameters of pulsed-dose-rate brachytherapy in locally advanced cervical cancer. *Int J Radiat Oncol Biol Phys* 71: 756-764, 2008.
10. Tanderup K, Nielsen SK, Nyvang GB, et al. From point A to the sculpted pear: MR image guidance significantly improves tumour dose and sparing of organs at risk in brachytherapy of cervical cancer. *Radiother Oncol* 94: 173-180, 2010.
11. Potter R, Georg P, Dimopoulos JC, et al. Clinical outcome of protocol based image (MRI) guided adaptive brachytherapy combined with 3D conformal radiotherapy with or without chemotherapy in patients with locally advanced cervical cancer. *Radiother Oncol* 100: 116-123, 2011.
12. Viswanathan AN, Erickson B, Gaffney DK, et al. Comparison and consensus guidelines for delineation of clinical target volume for CT- and MR-based brachytherapy in locally advanced cervical cancer. *Int J Radiat Oncol Biol Phys* 90: 320-328, 2014.
13. Fowler JF. The linear-quadratic formula and progress in fractionated radiotherapy. *Br J Radiol* 62: 679-694, 1989.
14. Viswanathan AN, Erickson BA. Three-dimensional imaging in gynecologic brachytherapy: a survey of the American Brachytherapy Society. *Int J Radiat Oncol Biol Phys* 76: 104-109, 2010.
15. Grover S, Harkenrider MM, Cho LP, et al. Image guided cervical brachytherapy: 2014 survey of the American brachytherapy Society. *Int J Radiat Oncol Biol Phys* 94: 598e604, 2016.
16. Kemikler G. History of Brachytherapy. *Turk J Oncol* 34 (Supp 1): 1-10, 2019.
17. Zolciak-Siwinska A, Kowalczyk A, Sikorska K, et al. Comparison of computed tomography with magnetic resonance imaging for imaging-based clinical target volume contours in cervical cancer brachytherapy. *Brachytherapy* 17: 667-672, 2018.
18. Viswanathan AN, Dimopoulos J, Kirisits C, et al. Computed tomography versus magnetic resonance imaging-based contouring in cervical cancer brachytherapy: results of a prospective trial and preliminary guidelines for standardized contours. *Int J Radiat Oncol Biol Phys* 68: 491-498, 2007.
19. Swanick CW, Castle KO, Vedam S, et al. Comparison of computed tomography and magnetic resonance imaging-based clinical target volume contours at brachytherapy for cervical cancer. *Int J Radiat Oncol Biol Phys* 96: 793-800, 2016.
20. Nesvacil N, Pötter R, Sturdza A, et al. Adaptive image guided brachytherapy for cervical cancer: a combined MRI-/CT-planning planning technique with MRI only at first fraction. *Radiother Oncol* 107: 75-81, 2013.
21. Choong ES, Bownes P, Musunuru HB, et al. Hybrid (CT/MRI based) vs. MRI only based image-guided brachytherapy in cervical cancer: Dosimetry comparisons and clinical outcome. *Brachytherapy* 15: 40-48, 2016.
22. Wang F, Tang Q, Lv G, et al. Comparison of computed tomography and magnetic resonance imaging in cervical cancer brachytherapy: a systemic review. *Brachytherapy* 16: 353-365, 2017.
23. Mohamed S, Nielsen SK, Fokdal LU, et al. Feasibility of applying a single treatment plan for both fractions in PDR image guided brachytherapy in cervix cancer. *Radiother Oncol* 107: 32-38, 2013.
24. Kirisits C, Lang S, Dimopoulos J, et al. Uncertainties when using only one MRI-based treatment plan for subsequent high-dose-rate tandem and ring applications in brachytherapy of cervix cancer. *Radiother Oncol* 81: 269-275, 2006.

25. Lang S, Nesvacil N, Kirisits C, et al. Uncertainty analysis for 3D image-based cervix cancer brachytherapy by repetitive MR imaging: assessment of DVH variations between two HDR fractions within one applicator insertion and their clinical relevance. *Radiother Oncol* 107: 26-31, 2013.

**Correspondence:**

Dr. Hazim Orhan KIZILKAYA  
Sisli Hamidiye Etfal Egitim ve Arastirma Hastanesi  
Radyasyon Onkolojisi Bölümü  
Sisli, ISTANBUL / TURKEY

Tel: (+90-533) 949 19 47

e-mail: orhankizilkaya959@yahoo.com