

Targeted Therapies are New Hope for Patients with Spinal Radionecrosis

Cemil HOCAZADE¹, Nuriye Y. OZDEMIR², Ozan YAZICI¹, Zeynep N. OZTEKIN³, Nurullah ZENGİN¹

¹ Ankara Numune Training and Research Hospital, Dept of Medical Oncology

² Ankara Yildirim Beyazıt University Faculty of Medicine, Dept of Medical Oncology

³ Ankara Numune Training and Research Hospital, Dept of Neurology, Ankara, TURKEY

Dear Editor

Most of the chemotherapy drugs are not able to pass through the blood brain barrier. Therefore, radiotherapy is a standard therapy for both primary and metastatic intracranial tumors. Currently, non-invasive methods such as stereotactic radiosurgery and whole brain radiotherapy have been used in the treatment of metastasis with low rate of neurological complications.¹ Radionecrosis is a late complication of radiotherapy occurring after one-three years following therapy.² Radionecrosis of the brain are more common, however central spinal necrosis may occur after radiotherapy and there are no standard therapy suggested for this complication.

Thirty nine years old female patient, in September 2008, who was given to 3060 cGY radiotherapy cervical region with a diagnosis of stage I Non-Hodgkin's lymphoma (follicular subtype, grade II). In August 2010, she was seen with left shoulder and neck paresthesia and paralysis of left upper extremity. Nodular type signal variation was detected in her left posterolateral part of cervical spinal cord on C3-4 intervertebral disc level, that was isointense on T2-weighted sequences and hyperintense on T1 sequence with cord on magnetic resonance imaging scans (MR) (Figure 1a,1b). Except this, there was no pathological evidence on control investigations. Muscle strength was improved to 4/5 with symptomatic treatment such as steroids and analgesics.

After four years, in august 2014, the patient was admitted to hospital with suddenly occurred left quadriplegia. There was no difference on cervical spinal MR between 2010 and 2014. In her neurological examination; muscle strength was 2/5 on left upper proximal extremity and 3/5 on distal extremity, 4/5 on right upper extremity, 4/5 on right lower extremity and 2/5 on left lower extremity. The cerebrospinal fluid was examined for leptomeningeal involvement of NHL. However, biochemistry, cytological and flow cytometry examination was normal. In addition to that there was no evidence of NHL recurrence in her radiological imaging and laboratory examinations. After that the diagnosis of the patient was established as biphasic course of radiation necrosis. Bevacizumab 5 mg/kg was administered to patient. Four following courses were given biweekly. After bevacizumab treatment patient's complaints were regressed and she has recovered. In her physical examination ECOG (Eastern Cooperative Oncology Group) performance status was degrade from 3-4 to 0-1 with minimally symptoms. Following treatment muscle strength was 4/5 on her left upper distal extremity and all of the others were 5/5. The neurological examination was similar with the previous sequels. Patient had full recovery of symptoms and signs related to radionecrosis with successful treatment with bevacizumab treatment.

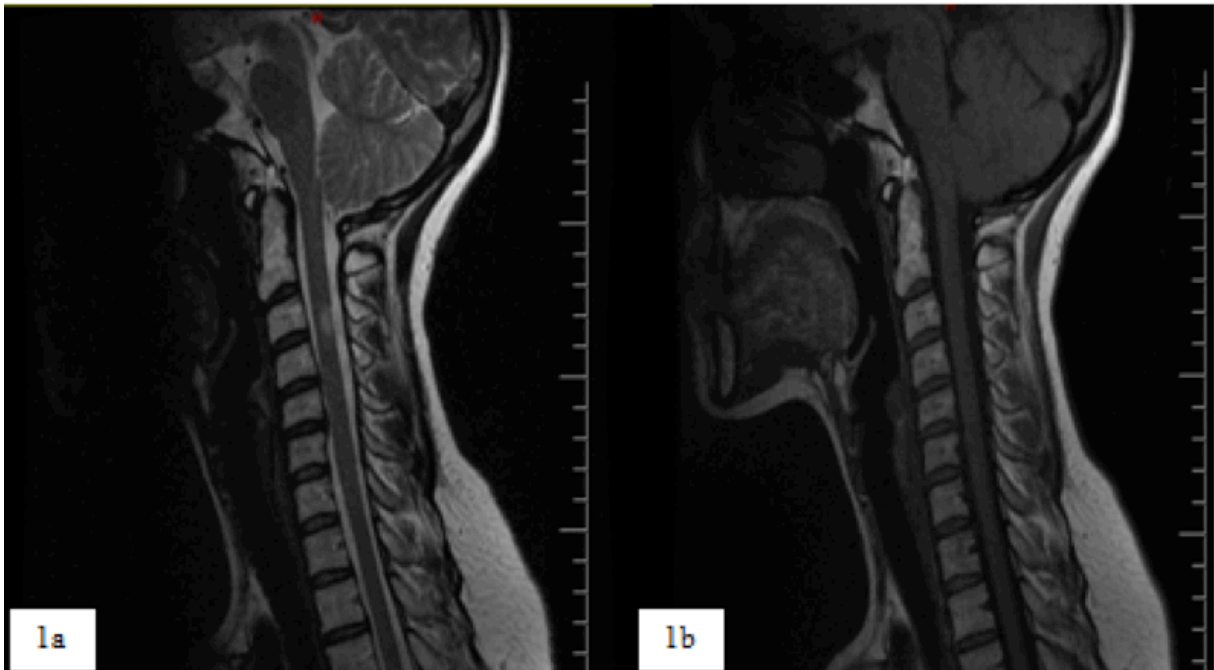


Figure 1. Lesion was detected as hyperintense on T1 images (1a) and isointense on T2 images (1b) on MRI scans

Whole brain radiotherapy and stereotactic radiosurgery are important treatment modalities for primary and metastatic brain tumors. Long term side effects might be detected following radiation therapy. Among these side effects radiation necrosis was the most frequently one. Treatment of radionecrosis is a challenge for clinicians.

Cerebral radionecrosis might usually occurs within a few months to until 3 years after treatment, however it might occurred within a shorter period after brachytherapy.^{1,2} After radiotherapy to spinal region, radionecrosis may occur within the following 8 years.⁶ In our case, biphasic clinical course was seen and loss of strength in the left upper limb occurred following 2 years after the first attack of radiotherapy. The second attack occurred 6 years after diagnosis, patients had loss of strength in four of her limbs. As our knowledge, the current case was the first one admitting to hospital with biphasic clinical course.

Clinical course of the disease is generally consistent with focal neurological defects and signs of increased intracranial pressure. Neurological complications occur in 2-32% of affected patients. Usually, symptoms are focal neurological signs confine with the tumor recurrence.¹ Our patient

was referred to our hospital with signs and symptoms similar to tumor recurrence and based on the clinical signs the relapse of NHL was considered as pre-diagnosis.

The gold standard of diagnosis is the evaluation of pathological biopsy from the lesion.² The most effective imaging tool is MRI for differential diagnosis because, white matter lesions appear more prominent on MRI. Computed tomography and PET-CT can also be used for differential diagnosis of radionecrosis.²⁻⁴ The current patient's lesion, consistent with radionecrosis, was seen hyperintense on T1 images and isointense on T2 images (Figure 1a, 1b).

Steroid was given as standard treatment of radionecrosis, however steroid might cause many complications. Therefore, the treatment with steroid is generally limited to a short time of period. For these reasons, alternative treatments such as antiplatelet and anticoagulant drugs, were investigated. Effects of these drugs were very limited for treatment of radionecrosis. Hyperbaric oxygen therapy is one of the alternative treatments being investigated. Bevacizumab as an anti-VEGF, has shown efficacy in treating central radionecrosis.^{5,6} Seventy-one cerebral necrosis patients treated with 4 cycles of

bevacizumab. Bevacizumab was well tolerated by patients and showed efficacy in the treatment of radiation necrosis.⁷ Except from cerebral necrosis, there was no report for using bevacizumab in cervical spinal radionecrosis. Following 4 cycles of bevacizumab therapy the current case neurological examination signs were recovered very well. The muscle strength of the patient was nearly normal, she could easily perform her daily activities.

As a conclusion, bevacizumab might be used for cervical spinal radionecrosis based on the clinical evidence related to successful treatment responses in cerebral necrosis.

REFERENCES

1. Fahrenholtz SJ, Stafford RJ, Maier F, et al. Laser Interstitial Thermal Therapy for Focal Cerebral Radiation Necrosis: A Case Report and Literature Review. *Int J Hyperthermia* 29: 324-335, 2013.
2. Keime-Guibert F, Napolitano M, Delattre JY. Neurological complications of radiotherapy and chemotherapy. *J Neurol* 245: 695-708, 1998.
3. Galldiks N, Stoffels G, Filss CP, et al. Role of O-(2-(18)F-fluoroethyl)-L-tyrosine PET for differentiation of local recurrent brain metastasis from radiation necrosis. *J Nucl Med* 53: 1367-1374, 2012.
4. Leeman JE, Clump DA, Flickinger JC, et al. Extent of perilesional edema differentiates radionecrosis from tumor recurrence following stereotactic radiosurgery for brain metastases. *Neuro Oncol* 15: 1732-1738, 2013.
5. Boothe D, Young R, Yamada Y, et al. Bevacizumab as a treatment for radiation necrosis of brain metastases post stereotactic radiosurgery. *Neuro Oncol* 15: 1257-1263, 2013.
6. Torcuator R, Zuniga R, Mohan YS, et al. Initial experience with bevacizumab treatment for biopsy confirmed cerebral radiation necrosis. *J Neurooncol* 94: 63-68, 2009.
7. Tye K, Engelhard HH, Slavin KV, et al. An analysis of radiation necrosis of the central nervous system treated with bevacizumab. *J Neurooncol* 117: 321-327, 2014.

Correspondence

Dr. Cemil HOCAZADE

Ankara Numune Egitim ve Arastirma Hastanesi

Tibbi Onkoloji Bölümü

06100 Altindag

Ankara / TURKEY

Tel: (+90-312) 508 46 03

Fax: (+90-312) 508 49 14

e-mail: cemilhocazade@gmail.com