

Acquired Ichthyosis Revealing an Underlying Hodgkin's Lymphoma

Aristóteles ROSMANINHO, Ana OLIVEIRA, Inês LOBO, Madalena SANCHES, Manuela SELORES

Centro Hospitalar do Porto-HSA, Department of Dermatology, Porto, PORTUGAL

ABSTRACT

Acquired ichthyosis is a nonhereditary cutaneous disorder characterized by dry, rough skin with scaling that involves significant areas of the body. The disease most commonly manifests in adulthood and usually represents malignancy, especially hematologic disease. We report a 48-year-old woman who presented to the dermatology out-patient clinic because of severe scaling of the skin with a "dirty" appearance. The subsequent study revealed an underlying Hodgkin's lymphoma.

Keywords: Acquired ichthyosis, Hodgkin's disease, Lymphoma

ÖZET

Hodgkin Lenfoma Zemininde Akkiz İktiyozis

Akkiz iktiyozis, vücudun büyük bölümünde pullanma, deride kuruluk ve kabalaşma ile karakterize nonherediter bir cilt hastalığıdır. Hastalık, çoğunlukla erişkin yaş grubunda, özellikle hematolojik malignansilerin belirtisi olarak ortaya çıkar. biz dermatoloji polikliniğine, ciltte "kirli" görünüm ve pullanma şikayeti ile başvuran 48 yaşındaki bayan hastayı rapor ettik. Daha sonraki süreçte hastanın Hodgkin lenfoma olduğu anlaşıldı.

Anahtar Kelimeler: Akkiz iktiyozis, Hodgkin hastalığı, Lenfoma

INTRODUCTION

Ichthyosis is a general term used to describe a large and heterogeneous group of cornification disorders that are genetic or acquired in nature and are characterized clinically by the formation of visible scales on significant portions of the body and an excessively dry skin.¹ In severe cases the skin resembles fish scales (“ichthys”, which is fish from Greek) and the patient complains about his “lizard skin”. The color of the scales varies from white to gray to brown and affects primarily the trunk and limbs being accentuated on the extensor surfaces and relatively sparing the flexures.²

Acquired ichthyosis can have a variety of underlying etiologies, including neoplastic, infectious, drugs, endocrine, metabolic, autoimmune, and malabsorptive states.³⁻⁸

CASE REPORT

A 48 year-old woman presented to our out-patient clinic with a diffuse symmetric scaling of the skin that had appeared in the prior three months. The desquamation was more prominent on the back and extensor surfaces of the limbs and spared the flexures. The scales were brown, fine, with curled up edges giving the skin a rough feel and a “dirty” appearance (Figure 1).

The clinical diagnosis of acquired ichthyosis was made. She complained about fatigue and weight loss in the last month and denied fever, night sweats or new drug intake.

On physical examination a 3 cm right inguinal adenomegaly was palpable (Figure 2). Her prior medical history was irrelevant.

Laboratory work-up showed an important inflammatory syndrome with a C-reactive protein of 97 mg/l (< 5), an erythrocyte sedimentation rate of 108 mm/h (0-19), hemoglobin of 10.6 g/dl (11.5-16.5) and a α 2-globulin of 22 g/l (3.6-13.2). Beta-2-microglobulin was 2.3 mg/L (0-1.9). Electrolytes, renal and hepatic functions were normal.

Computed tomography of the chest, abdomen, and pelvis revealed multiple mediastinal, mesenteric, iliac, and inguinal lymphadenopathies. An open inguinal lymph node biopsy was performed and the hematoxylin - eosin stain showed a neoplastic proliferation of Reed- Sternberg cells and a polymorphous cellular infiltration with eosinophils, neutrophils and plasma cells. Immunohistochemical staining was positive for CD30, CD15, and negative for LCA (leukocyte common antigen), CD3, and CD20. We diagnosed her as a mixed-cellularity Hodgkin’s lymphoma. Bone marrow biopsy showed hypoplasia with no other alterations. Serological tests for HIV, EBV, CMV, HBV, HCV, and tre-

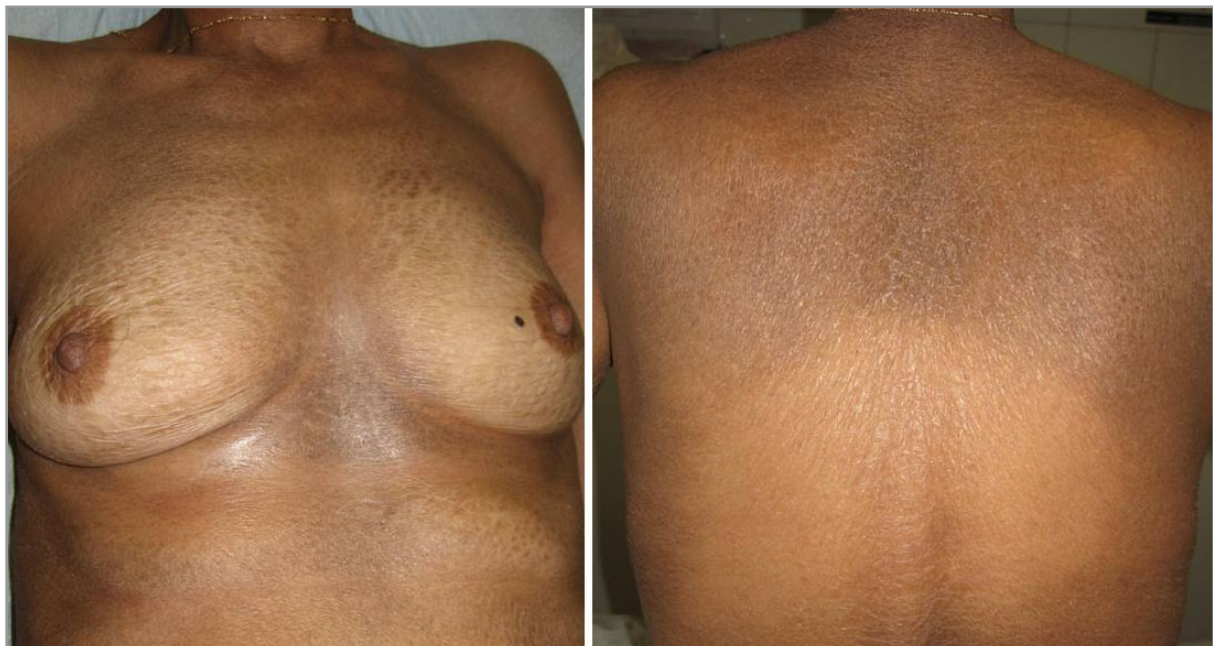

Figure 1. Diffuse scaling with a “dirty” appearance.

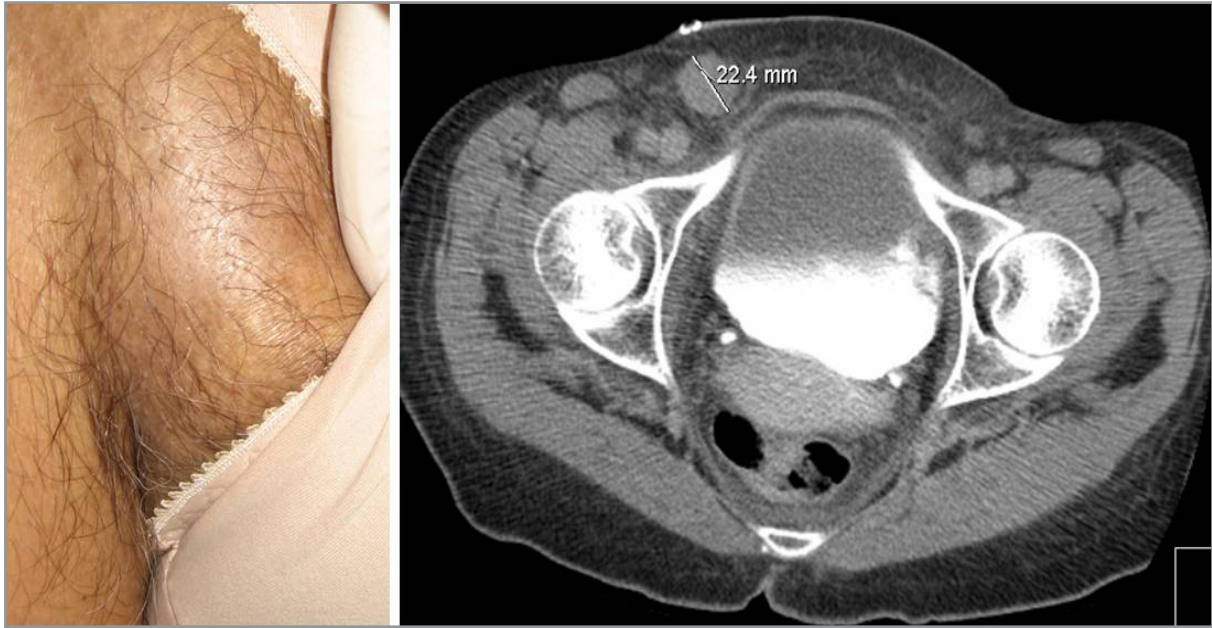


Figure 2. Inguinal adenopathy

ponema pallidum were negative. Skin biopsy on an area of maximal hyperkeratosis showed slightly epidermal atrophy with orthokeratotic hyperkeratosis and decreased granular cell layer thickness (Figure 3). Those findings confirmed the diagnosis of acquired ichthyosis.

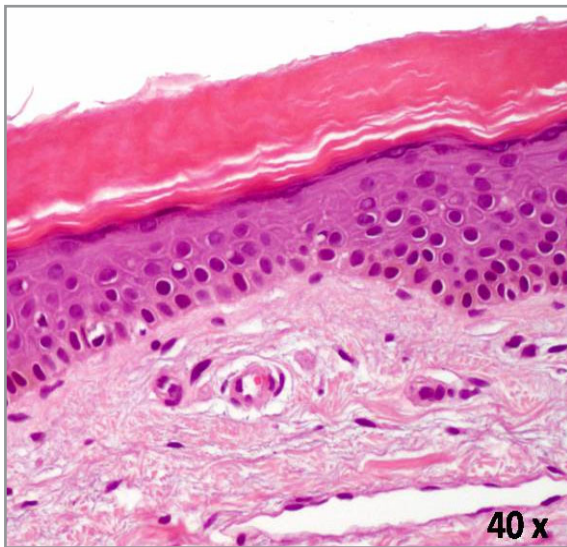


Figure 3. Hematoxylin and eosin stain showing orthokeratotic hyperkeratosis and decreased granular cell layer thickness of the epidermis

The patient was treated with ABVD chemotherapy scheme (Adriamycin, Bleomycin, Vinblastine, Dacarbazine) and resolution of the skin lesions was observed. After 8 months of follow-up the skin lesions didn't recur (Figure 4).

DISCUSSION

The first step in evaluating an adolescent or adult with new-onset ichthyosis is differentiating acquired ichthyosis from other causes of new-onset ichthyosis. Essentially, most hereditary forms of ichthyosis will present till adolescence, there is a positive family history and it is possible to find an association with atopic manifestations, such as asthma, eczema or hay fever.^{2,9,10} Acquired forms of the disease are extremely rare and are almost observed in adults.¹¹ They have a later onset and are associated with many systemic diseases, such as cancer¹², autoimmune and inflammatory diseases¹³ (sarcoidosis, graft-versus-host disease, systemic lupus erythematosus, dermatomyositis), infections⁴ (leprosy, HIV, human T-lymphotropic virus 1 and 2), metabolic diseases^{1,14} (chronic renal failure, hypothyroidism, diabetes mellitus), and drugs^{15,16} such as cholesterol lowering agents (nicotinic acid, triparanol). The most common types of cancer include Hodgkin's disease (accounts almost 80% of

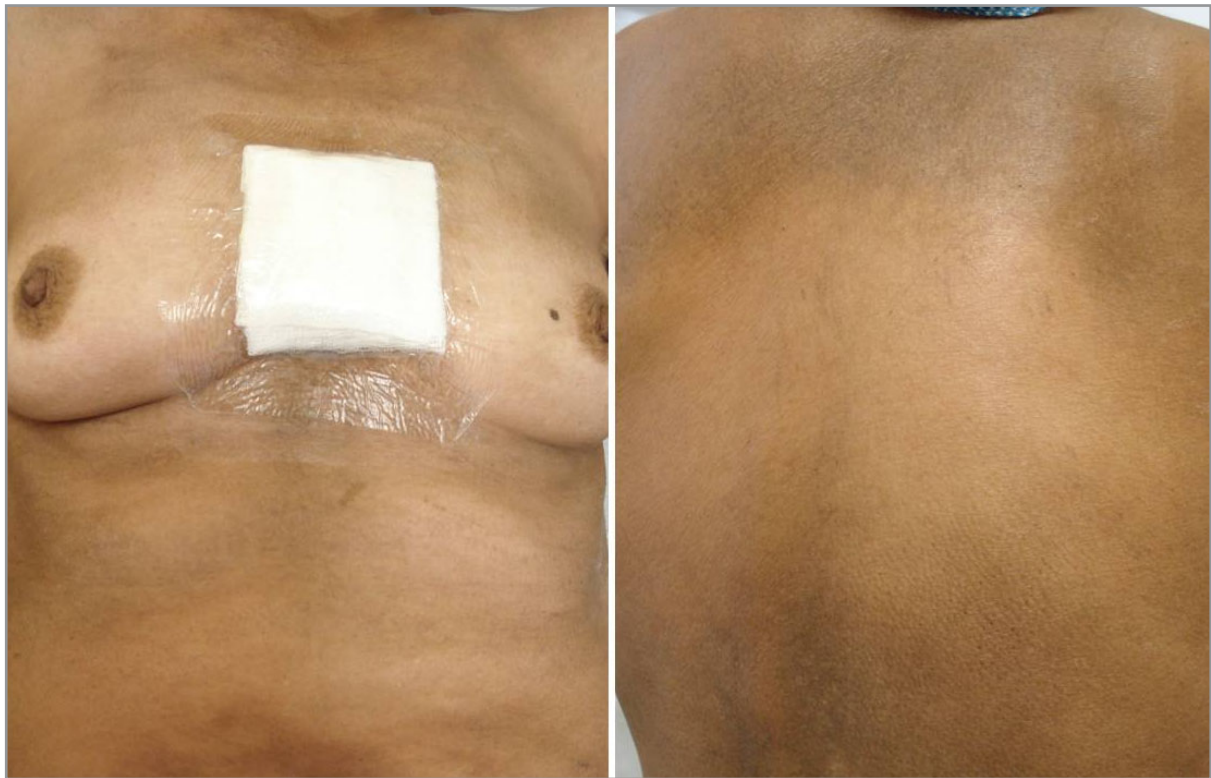

Figure 4. Resolution of the skin lesions after chemotherapy

the malignant hemopathies)¹⁷, non-Hodgkin's lymphoma, Kaposi's sarcoma, multiple myeloma, and carcinomas of breast, lung, ovary, and cervix.^{3,11,18} Thus, new-onset ichthyosis at any age, should prompt further investigation due to associated internal disease. The ichthyosis usually occurs simultaneously with or after the diagnosis of the lymphoma but it can precede it in by one year or more.¹⁹

In our case, a Hodgkin's lymphoma was revealed by acquired ichthyosis, which could constitute a relevant but unusual cutaneous manifestation of lymphoproliferative disorders. The underlying pathophysiologic mechanism remains unclear, although several complex factors seem to be involved. The process of cornification is complex with multiples enzymes performing sequential activities in the process of creating and then breaking down the stratum corneum. The function of these enzymes can be affected by alterations in the water content or lipid composition of the intercellular material. A metabolic disruption or autoimmune attack to these enzymes can be a possible explanation for the ap-

pearance of the ichthyosis. Abnormal low fasting levels of vitamin A in the blood and disturbance of hepatic functions have been described in patients with ichthyosis.²⁰ Some authors found that ichthyosis in patients with Hodgkin's disease may indicate hepatic involvement by Hodgkin's disease [8] and that epidermal and dermal lipogenesis can be diminished in patients with acquired ichthyosis and Hodgkin's disease.²¹ Therefore impaired vitamin A metabolism and an ineffective lipogenesis are additional explanations, however we did not have an access to the vitamin A blood levels of our patient. Furthermore, transforming growth factor- α produced by tumor cells has been implicated in the pathogenesis of the dermatosis.²² In addition, the paraneoplastic character of the disease was proved by the resolution of the skin lesions after the first cycle of chemotherapy.

REFERENCES

1. Traupe H. (ed.). The ichthyosis. A Guide to Clinical Diagnosis, Genetic Counseling and Therapy. Berlin: Springer-Verlag, 1989: 139-153.

2. Ziprkowski L, Feinstein A. A survey of ichthyosis vulgaris in Israel. *Br J Dermatol* 86: 1-8, 1972.
3. Flint G, Flam M, Soter N. Acquired ichthyosis- a sign of nonlymphoproliferative malignant disorders. *Arch Dermatol* 111: 1446-1447, 1975.
4. Coldiron BM, Bergstresser PR. Prevalence and clinical spectrum of skin disease in patients infected with the human immuno-deficiency virus. *Arch Dermatol* 125: 357-361, 1989.
5. Elias PM, Brown BE, Ziboh VA. The permeability barrier in essential fatty acid deficiency; evidence for a direct role for linoleic acid in barrier function. *J Invest Dermatol* 74: 230-233, 1980.
6. Griffiths WAD, Judge MR, Leigh IM. Disorders of keratinization. In: Champion RH, Burton JL, Burns DA, Breathnach SM, editors. *Textbook of Dermatology*. 6th edition. Malden, Mass: Blackwell; 1998:1483, 1529.
7. Tlacuilo-Parra JA, Guevara-Gutierrez E, Salazar-Paramo M. Acquired ichthyosis associated with systemic lupus erythematosus. *Lupus* 13: 270-273, 2004.
8. Aram H. Acquired ichthyosis and related conditions. *Int J Dermatol* 23: 458-461, 1984.
9. Kuokkanen K. Ichthyosis vulgaris. A clinical and histopathological study of patients and their close relatives in the autosomal dominant and sex-linked forms of the disease. *Acta Derm Venereol (Suppl)(Stockh)* 62: 1-72, 1969.
10. Shwayder T, Ott F. All about ichthyosis. *Pediatr Clin North Am* 38: 835-857, 1991.
11. Schwartz RA, Williams ML. Acquired ichthyosis: a marker for internal disease. *Am Fam Physician* 29: 181-164, 1984.
12. Ghislain PD, Roussel S, Marot L, et al. Acquired ichthyosis disclosing Hodgkin's disease: simultaneous recurrence. *Presse Med* 31: 1126-1128, 2002.
13. Font J, Bosch X, Ingelmo M, et al. Acquired ichthyosis with systemic lupus erythematosus. *Arch Dermatol* 126: 829, 1990.
14. Yosipovitch G, Hodak E, Vardi P, et al. The prevalence of cutaneous manifestations in IDDM patients and their association with diabetes risk factors and microvascular complications. *Diabetes Care* 21:1032, 1998.
15. Finkelstein W, Isselbacher KJ. Drug therapy: cimetidine. *N Engl J Med* 299: 992-996, 1978.
16. Winkelmann RK, Perry HO, Achor RWP, Kirby TJ. Cutaneous syndromes produced as side-effects of triparanol therapy. *Arch Dermatol* 87: 372-377, 1963.
17. Kurzrock R, Cohen PR. Mucocutaneous paraneoplastic manifestations of hematologic malignancies. *Am J Med* 99: 207-216, 1995.
18. Roselino AM, Souza CS, Andrade JM, et al. Dermatomyositis and acquired ichthyosis as paraneoplastic manifestations of ovarian tumor. *Int J Dermatol* 36: 611-614, 1997.
19. Lucker GHP, Steijlen PM. Acrokeratosis paraneoplastica (Bazex syndrome) occurring with acquired ichthyosis in Hodgkin's disease. *Br J Dermatol* 133: 322-325, 1995.
20. Van Dijk E. Ichthyosiform atrophy of the skin associated with internal malignant diseases. *Dermatologica* 127: 413-428, 1963.
21. Cooper MF, Wilson PD, Hartop PJ, Shuster S. Acquired ichthyosis and impaired dermal lipogenesis in Hodgkin's disease. *Br J Dermatol* 102: 689-93, 1980.
22. Estines O, Grosieux-Dauger C, Derancourt C, et al. Ichtyose acquise paranéoplasique révélatrice d'un lymphome non hodgkinien. *Ann Dermatol Venereol* 128: 31-34, 2001.

Correspondence

Aristóteles David Neiva Rosmaninho
 Serviço de Dermatologia
 Centro Hospitalar do Porto-HSA, EPE
 Edifício das consultas externas, Ex CICAP, Rua D. Manuel II
 Porto / PORTUGAL

Tel: +351226097429
 Fax: +351226097429
 e-mail: arisrosmaninho@gmail.com