

Expression of the Fragile Histidine Triad Gene in Laryngeal Carcinoma

Ediz TUTAR¹, Erkan KARATAS², Tekin BAGLAM²

¹ Gaziantep University, Faculty of Medicine, Department of Pathology

² Gaziantep University, Faculty of Medicine, Department of Otolaryngology– Head and Neck Surgery, Gaziantep, TURKEY

ABSTRACT

The aim of this study was to investigate Fragile Histidine Triad Gene (FHIT) expression in laryngeal squamous cell carcinoma. The paraffin embedded tissue blocks of 64 laryngeal squamous cell carcinoma specimens were enrolled in the study. FHIT expression was detected by an immunohistochemical method. Rabbit polyclonal antibody was used for immunohistochemical study. FHIT expression was low in 40.6% of patients and high in 59.6% of patients. Results were compared with clinicopathological variables. There was a significant correlation between high FHIT expression and lymph node metastasis ($p < 0.05$). There was no significant correlation between FHIT expression and age, histological grade, perineural invasion and vascular invasion. In conclusion, FHIT may be accepted to play a role in laryngeal squamous cell carcinoma tumorigenesis as a tumor suppressor gene.

Keywords: Fragile Histidine Triad Protein, Laryngeal neoplasms, Metastasis

ÖZET

Larinks Karsinomlarında Fragil Histidine Triad Gen Ekspresyonu

Bu çalışmanın amacı, skuamöz hücreli larinks karsinomlarında Fragile Histidine Triad Gene (FHIT) gen ekspresyonunu araştırmaktır. Bu çalışmaya 64 skuamöz hücreli larinks karsinomu spesmenine ait parafine gömülmüş doku blokları dahil edilmiştir. FHIT ekspresyonu immunhistokimyasal yöntem ile çalışılmıştır. İmmunhistokimyasal çalışmada tavşan poliklonal antikor kullanılmıştır. FHIT ekspresyonu hastaların %40.6'sında düşük ve hastaların %59.6'unda yüksektir. Sonuçlar, klinikopatolojik değişkenlerle karşılaştırılmıştır. Yüksek FHIT ekspresyonu ile lenf nodu metastazı arasında anlamlı bir ilişki mevcuttur ($p < 0.05$). FHIT ekspresyonu ile yaş, histolojik derece, perinöral invazyon vasküler invazyon arasında anlamlı bir ilişki mevcut değildir. Sonuç olarak FHIT 'in skuamöz hücreli larinks karsinomu tümör oluşumunda, tümör supresör gen olarak rol oynadığı kabul edilebilir.

Anahtar Kelimeler: Fragile Histidine Triad Protein, Larinks neoplazmları, Metastaz

INTRODUCTION

The establishment of prognostic factors is indispensable in oncology. These factors are useful to predict the response to therapy and to plan new treatment and prevention strategies. As for other cancers of the body, many studies have been done on laryngeal cancer to determine the prognostic significance of many clinical and pathological factors.^{1,2}

Genetic alterations are crucial in the cancer disease. Understanding the genetic aspects of the cancer will improve not only its treatment, but also help predict the prognosis of the disease. This is true for the head and neck cancers including the laryngeal squamous cell carcinoma (LSCC) which is the most common cancer of the larynx.

The fragile histidine triad (FHIT) gene is located at chromosome 3p14.2. FHIT encompasses FRA3B, the most active common fragile site in the human genome.^{3,4} It had been proposed as a tumor suppressor gene encoding a 1.1 kb cDNA.⁴ Siprashvilli et al revealed that tumorigenesis of cancer cells is inhibited by replacement of the FHIT gene, and so FHIT may be accepted as a tumour suppressor gene.⁵

The reduced expression of FHIT has been identified in a number of carcinoma such as lung, breast, cervix, nasopharynx, prostate carcinomas and malignant mesothelioma.⁶⁻¹¹ Tobacco smoke is a risk factor of the larynx carcinoma.¹² Soma et al showed that the FHIT gene of esophageal mucosal cells was inactivated by exposure to nicotine.¹³ Loss of FHIT protein expression has also been reported in some precancerous lesion of the oral cavity.¹⁴

In this study we examined the immunohistochemical expression of FHIT protein in laryngeal squamous cell carcinomas and compared the relationship between FHIT expression and conventional clinicopathologic prognostic parameters.

MATERIALS AND METHODS

64 patients with squamous cell carcinoma of the larynx were randomly selected from pathology files of our hospital. All the patients included in our study had undergone total or partial laryngectomy depending on the extent of the lesion and the neck dissection. All of them had single primary tumor and none had undergone treatment prior to the surgery. T1 to T4 cases were included in this study.

The most representative paraffin embedded block of tissue was chosen for each case and 5 µm sections were cut for immunohistochemistry. The FHIT antibodies (rabbit polyclonal antibody, Neomarkers, USA, dilution 1: 150) were used.

The tissue sections were deparaffinized in xylene and rehydrated through graded concentrations of alcohol. The sections were boiled in a microwave oven for 20 min., in citrate buffer solution (10 mmol/L, pH= 6.0). Endogenous peroxidase activity was blocked by exposing sections to a 0.3% solution of hydrogen peroxidase in phosphate-buffered saline (PBS) for 10 minutes at room temperature.

Sections were incubated with the primary antibody for 40 min at room temperature. Biotinylated goat anti-polyvalent and streptavidin peroxidase (Lab Vision, USA) were applied for 10 minutes. Between incubations, the sections were washed in PBS (pH 7.00) for 3 min. Sites of peroxidase activity were visualized with 3,3-diaminobenzidine (DAB plus, Lab Vision). The sections were counterstained with hematoxylin and mounted. Normal breast tissue was used as positive control. Negative controls were incubated with Tris-buffered saline instead of primary antibody.

Evaluation of immunohistochemistry was done by one pathologist who was neither aware of original diagnosis nor of clinical data. Immunohistochemical staining was graded, as reported previously by Otero- Garcia et al.¹⁵ The intensity of the staining in the neoplastic cells was graded as 0= no significant staining, 1= moderate staining, 2= intense staining. The extent of staining was graded as follows: 0= ≤ 10%; 1= 11-49%; 2= ≥ 50%. Scores of intensity and extent of staining were added for each tumor. A total score of 2 or less was considered as low FHIT expression. If the total score was greater than 2 it was considered to be high expression of FHIT.

The chi-square test was used for statistical analysis. Data were analyzed using SPSS for Windows 10.0. Fisher's exact test was used on 2x2 tables when an expected frequency of a cell was less than 5. All differences were considered significant if $p < 0.05$.

RESULTS

The main clinicopathologic features of our series of patients are summarized in Table 1. We analyzed

paraffin embedded tissue blocks of 64 patients with squamous cell carcinoma of the larynx. The median age of the patients was 56.6 (± 10.98). Sixty of the patients (93.8%) were male and 4(6.2%) were female. FHIT expression was low in 40.6% of patients and high in 59.6% of patients (Figure 1, 2).

In our statistical analysis FHIT expression was separately compared with age, T stage, histological grade, vascular and perineural invasion, lymph node metastasis (Table 2).

High FHIT expression was significantly associated with lymph node metastasis ($p = 0.035$).

FHIT expression was not statistically correlated with histological grade ($p = 0.953$), perineural invasion ($p = 0.331$), and vascular invasion ($p = 0.663$). There was no correlation between FHIT expression and age ($p = 0.358$).

DISCUSSION

This study was designed to evaluate abnormal FHIT expression as a prognostic marker in patients with laryngeal carcinoma. FHIT expression was low in 40.6% of our patients and high in 59.6% of our patients. High FHIT expression was significantly associated with lymph node metastasis.

The FHIT gene is a candidate tumor suppressor gene, although its precise mechanism of action remains unclear. Restoration of this gene expression in tumor cells has yielded conflicting results. These conflicting data suggest that the mechanisms involved with the function of the FHIT gene may be different from those of other classic tumor suppressor genes such as p53 and Rb1.^{16,17} Sard et al. reported that the FHIT gene is involved in the regulation of the cell cycle and that its tumor suppressor activity is derived from its proapoptotic activity.¹⁸ However, Otterson et al. evaluated the function of the FHIT gene and did not discover any regulation of the cell cycle or function with respect to induction of apoptosis.¹⁷ These varied results may reflect that FHIT functions in a tissue-specific fashion or at a particular point in the multistage process of carcinogenesis.

T stage and lymph node metastasis negatively affects disease-specific survival in the laryngeal carcinoma. Patients older than 65 years of age have short survival rates.¹⁹ In our study, it was found that there was no statistically significant relationship

Table 1. Clinicopathologic data of 64 patients with laryngeal squamous cell carcinoma

Characteristics	Patients (%)
Patients	64
Total no	56.64 (32-76)
Median age (years) [range]	60 (93.8%)
Male	
Female	4 (6.2%)
Histological grade	
Well differentiated	26 (40.6%)
Moderately differentiated	21 (32.8%)
Poorly differentiated	17 (26.6%)
T stage	
T1	5 (7.8%)
T2	16 (25.0%)
T3	24 (37.5%)
T4	19 (29.7%)
Lymph node metastasis	
Absent	38 (59.4%)
Present	26 (40.6%)
Vascular invasion	
Absent	45 (70.3%)
Present	19 (29.7%)
Perineural invasion	
Absent	52 (81.3%)
Present	12 (18.7%)

between age of the patient, T stage of the tumor and FHIT expression. In a previous study of 103 patients with cervical carcinoma, it was found that reduced FHIT expression was significantly associated with lymph node metastasis.⁸

Low levels of FHIT expression has been found in a high percentage of high-grade squamous epithelial neoplasia in many studies.^{6,8,15,21} A few studies has been showed that FHIT expression was associated with locoregional recurrence paradoxically in head and neck squamous cell carcinoma (HNSCC).^{15,20}

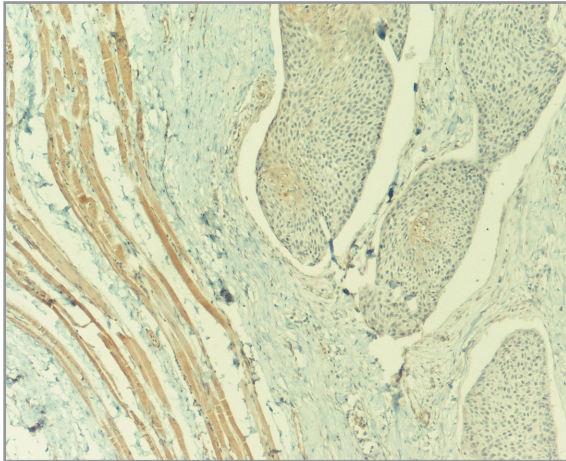


Figure 1. Low cytoplasmic staining with FHIT in a laryngeal squamous cell carcinoma with internal control contrast (Immunohistochemistry x100).

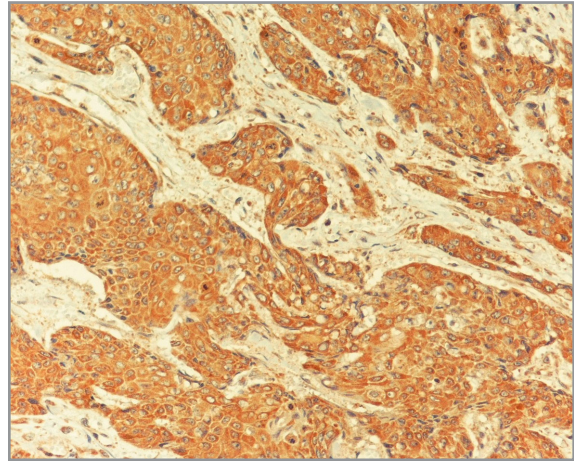


Figure 2. Very strong cytoplasmic immunoreactivity with FHIT at laryngeal squamous cell carcinoma (Immunohistochemistry x200).

Tai et al. found that patients classified as high risk who had a FHIT-negative tumor experienced loco-regional recurrence less often (18%) than did high-risk patients who had a FHIT-positive tumor (33%).²⁰ Otero-Garcia et al. implicated that overexpression of p53 predicted a trend toward an improved prognosis, whereas no reduction in FHIT expression predicted a significantly poorer outcome in patients with advanced oropharyngeal cancer.¹⁵ We included both glottic cancers and supraglottic cancers for researching the association between FHIT expression and lymph node metastasis. However it would be unfair to conduct a prospective study for glottic cancers and supraglottic cancers.

Reports on the role of FHIT in the head and neck cancers are not uniform. Mineta et al. found that FHIT expression was not correlated with prognosis, lymph node status, age, histologic grade, stage, tumor size in head and neck carcinoma. They showed that low FHIT expression correlated with high Ki-67 expression, suggesting that neoplastic cells with low FHIT expression may have high proliferation potential.²¹

Lee et al. investigated the expression of FHIT in the squamous cell carcinomas of tongue by immunohistochemistry. They reported that loss of FHIT expression was seen in 68% of patients. They also emphasized the loss of FHIT as a negative prognostic indicator for clinical outcome.²²

Otero-Garcia et al. showed that the overall survival of patients with FHIT positive tumors was significantly worse when compared to the patients with FHIT negative tumors in advanced oropharyngeal carcinomas.¹⁵ Furthermore all the patients with distant metastasis had FHIT positive tumors. In our series 67.2 % of the patients had advanced stage tumors (T3-4). Our findings also support the study of Otero-Garcia et al in that high FHIT expression was associated with metastasis.¹⁵

Vascular invasion is the most important histopathological parameter to determine lymph node metastasis in larynx carcinoma. Therefore pathologists must spend much effort to report vascular invasion accurately.

We found that high FHIT expression was significantly associated with lymph node metastasis ($p=0.035$). These data suggest that such expression of FHIT may correlate with increased lymph node metastasis ; however, studies with larger number of patients will be needed to establish this finding.

Dumon et al. reported that viral FHIT gene therapy prevents tumor development in the FHIT-deficient mice. FHIT gene therapy might be effective in the treatment of the carcinoma including laryngeal carcinoma.²³

In conclusion, our study revealed that laryngeal cancers have alterations in FHIT expression. FHIT may be accepted to play a role in laryngeal squamo-

Table 2. Correlation between FHIT-expression and other histopathologic parameters

Parameter	Low FHIT –expression (n= 26)	High FHIT –expression (n= 38)	p value
Age			
≤ 50	12 (18.8%)	12 (18.8%)	p= 0.358 (NS)
> 50	14 (21.9%)	26 (40.6%)	
Histological grade			
Well differentiated	10 (15.6%)	16 (25%)	p=0.953 (NS)
Moderately differentiated	9 (14.1%)	12 (18.8%)	
Poorly differentiated	7 (10.9%)	10 (15.6%)	
T stage			
T1-2	9 (14.1%)	12 (18.8%)	p= 1 (NS)
T3-4	17 (26.6%)	26 (40.6%)	
Lymph node metastasis			
Absent	20 (31.3%)	18 (28.1%)	p= 0.035
Present	6 (9.4%)	20 (31.3%)	
Vascular invasion			
Absent	17 (26.6%)	28 (43.8%)	p=0.663 (NS)
Present	9 (14.1%)	10 (15.6%)	
Perineural invasion			
Absent	23 (35.9%)	29 (45.3%)	p=0.331 (NS)
Present	3 (4.7%)	9 (14.1%)	

NS: nonsignificant

us cell carcinoma. However, the exact molecular mechanism of FHIT function is unclear and remains to be elucidated. Understanding the functional status of the FHIT proteins may lead to development of new therapeutic options in the future.

REFERENCES

- Vermund H, Krajci P, Eide TJ, Winther F. Laryngectomy whole organ serial sections--histological parameters correlated with recurrence rate. *Acta Oncol* 43: 98-107, 2004.
- Yilmaz T, Hosal AS, Gedikoğlu G, et al. Prognostic significance of vascular and perineural invasion in cancer of the larynx. *Am J Otolaryngol* 19: 83-88, 1998.
- Pekarsky Y, Zanesi N, Palamarchuk A, et al. FHIT: from gene discovery to cancer treatment and prevention. *Lancet Oncol* 3: 748-754, 2002.
- Ohta M, Inoue H, Cottecelli MG, et al. The FHIT gene, spanning the chromosome 3p14.2 fragile site and renal carcinoma associated t(3;8) breakpoint, is abnormal in digestive tract cancers. *Cell* 84: 587-597, 1996.
- Siprashvili Z, Sozzi G, Barnes LD, et al. Replacement of Fhit in cancer cells suppresses tumorigenicity. *Proc Natl Acad Sci USA* 94: 13771-13776, 1997.
- Mascaux C, Martin B, Verdebout JM, et al. Fragile histidine triad protein-expression in nonsmall cell lung cancer and correlation with Ki-67 and with p53. *Eur Respir J* 21: 753-758, 2003.
- Guler G, Uner A, Guler N, et al. The fragile genes FHIT and WWOX are inactivated coordinately in invasive breast carcinoma. *Cancer* 100: 1605-1614, 2004.
- Huang LW, Chao SL, Chen TJ. Reduced FHIT-expression in cervical carcinoma: correlation with tumor progression and poor prognosis. *Gynecol Oncol* 90: 331-337 2003.
- Deng YF, Tian F, Lu YD, et al. Mutation and abnormal expression of the fragile histidine triad gene in nasopharyngeal carcinoma. *Laryngoscope* 111: 1589-1592, 2001.

10. Fouts RL, Sandusky GE, Zhang S, et al. Down-regulation of fragile histidine triad-expression in prostate carcinoma. *Cancer* 97: 1447-1452, 2003.
11. Tutar E, Kiyici H. Role of fragile histidine triad protein expression in pathogenesis of malignant pleural mesothelioma. *Pathology* 40: 42-45, 2008.
12. Altieri A, Bosetti C, Talamini R, et al. Cessation of smoking and drinking and the risk of laryngeal cancer. *Br J Cancer* 87: 1227-1229, 2002.
13. Soma T, Kaganoi J, Kawabe A, et al. Nicotine induces the fragile histidine triad methylation in human esophageal squamous epithelial cells. *Int J Cancer* 119: 1023-1027, 2006.
14. Tanimoto K, Hayashi S, Tsuchiya E, et al. Abnormalities of the FHIT gene in human oral carcinogenesis. *Br J Cancer* 82: 838-843, 2000.
15. Otero-Garcia JE, Youssef E, Enamorado II, et al. Prognostic significance of p53 and FHIT in advanced oropharyngeal carcinoma. *Am J Otolaryngol* 25: 231-239, 2004.
16. Wu R, Connolly DC, Dunn RL, Cho KR. Restored-expression of fragile histidine triad protein and tumorigenicity of cervical carcinoma cells. *J Natl Cancer Inst* 92: 338-344, 2000.
17. Otterson GA, Xiao GH, Geradts J, et al. Protein-expression and functional analysis of the FHIT gene in human tumor cells. *J Natl Cancer Inst* 90: 426-432, 1998.
18. Sard L, Accornero P, Tornielli S, et al. The tumor suppressor gene FHIT is involved in the regulation of apoptosis and in cell cycle control. *Proc Natl Acad Sci USA* 96: 8489-8492, 1999.
19. Layland MK, Sessions DG, Lenox J. The influence of lymph node metastasis in the treatment of squamous cell carcinoma of the oral cavity, oropharynx, larynx, and hypopharynx: N0 versus N+. *Laryngoscope* 115: 629-639, 2005.
20. Tai SK, Lee JI, Ang KK, et al. Loss of FHIT-expression head and neck squamous cell carcinoma and its potential clinical implication. *Clin Cancer Res* 10: 5554-5557, 2004.
21. Mineta H, Miura K, Takebayashi S, et al. Low-expression of fragile histidine triad gene correlates with high proliferation in head and neck squamous cell carcinoma. *Oral Oncol* 39: 56-63, 2002.
22. Lee JI, Soria JC, Hassan K, et al. Loss of FHIT -expression is a predictor of poor outcome in tongue cancer. *Cancer Res* 61: 837-841, 2001.
23. Dumon KR, Ishii H, Fong YYL, et al. FHIT gene therapy prevents tumor development in Fhit-deficient mice. *Proc Natl Acad Sci USA* 98: 3346-3351, 2001.

Correspondence

Dr. Ediz TUTAR

Gaziantep Universitesi Tıp Fakültesi

Patoloji Anabilim Dalı

27310 Gaziantep / TURKEY

e-mail: tutar@gantep.edu.tr

Tel.: (+90.342) 360 60 60 ext.77167

Fax : (+90.342) 360 39 18