

Charcot Joint of the Spine with Long Term Survival and Return to Near Full Function

Russell P. GOLLARD¹, Larry ROSEN², John ANSON³

¹ Cancer and Blood Specialists of Nevada, Department of Medical Oncology and Hematology

² Mike O'Callaghan Federal Hospital, Department of Diagnostic Radiology

³ Western Regional Center for Brain and Spine Surgery, Department of Neurosurgery
Henderson, Nevada, USA

ABSTRACT

Charcot joints of the spine are rare entities which mimic low grade soft tissue malignancies by appearing as a destructive mass lesion on radiographic studies. We report a 42-year-old diabetic female, who presented with a mass-like lesion of the thoracic spine extending into the posterior mediastinum. She presented with hemiplegia. With conservative treatment and without mechanical stabilization or instrumentation of the spine, the patient was able to undergo rehabilitation and is alive ten years after presentation.

Key Words: Charcot joint, Soft tissue malignancies

ÖZET

Omurga Charcot Eklemine Uzun Süreli Sağkalım ve Fonksiyonların Tama Yakın Geri Kazanımı

Omurgalarda görülen Charcot eklemleri oldukça nadir görülen lezyonlardır ve radyografik incelemelerde düşük grade'li kas iskelet sistemi tümörlerini taklit eden destrüktif kitle lezyonu şeklinde görüntülenirler. Bu olgu sunumunda torasik vertebradan posterior mediastene uzanan bir kitle lezyonu ile başvuran 42 yaşında diabetik bir kadın hasta rapor edilmektedir. Bu olguda hemipleji mevcuttu ve omurga stabilizasyonu ile birlikte konservatif tedavi uygulanan hasta, rehabilitasyon altında, tanı konduğu andan itibaren on yıldır yaşamaktadır.

Anahtar Kelimeler: Charcot eklemi, Yumuşak doku malignansileri

INTRODUCTION

Charcot joints are characterized by joint destruction and denervation in the affected area. Charcot joints of the spine can appear to be low grade musculoskeletal malignancies both by their destructive appearance on imaging studies and by their histologic appearance. This “painless destruction” may occur anywhere in the body, though “tabes dorsalis” in the diabetic patient is the most common clinical presentation. A mass lesion may result, with fragmented bone and cartilage. Neuropathic spinal arthropathy, or charcot joint of the spine has been described in case reports and small series.¹⁻¹¹ Spinal charcot arthropathy is usually post-traumatic in origin, and often there is underlying systemic disease, such as diabetes mellitus, collagen vascular disease, quadriplegia or paraplegia.¹⁻¹¹ Charcot joints typically develop slowly in areas of painless instability without inflammation, but infection can supervene. Generally, instrumentation is required as instability is progressive.

CASE REPORT

A 53-year-old female initially presented with lower extremity paralysis and serum glucose of over 600. Computed tomography revealed a destructive mass anterior to the T-4 vertebral body compressing the

spinal cord with extension into the posterior mediastinum. She also had numbness of the legs, which progressed until the patient could feel nothing below the mid-thoracic region. Though she had no sensation, she felt “electric shocks” traveling up and down her spine. She could neither stand nor support her weight. Bowel and bladder control were intact. She had chronic, non-radiating lower back pain. Her greatest weight was 525 pounds, secondary to an eating disorder.

Laboratory studies were normal at the time of presentation except for the hyperglycemia noted above. A chest x-ray initially revealed a small pneumonia on the right side, as well as a possible retrocardiac chest mass. CT scans of the chest and myelograms showed an 8 cm mass anterior to the spine with partial destruction of the T3 and the T4 vertebral bodies. There was obliteration of a fat plane between the posterior mediastinum and anterior vertebral body (Figures 1A, 1B). This mass was continuous, surrounding T3 and T4. Air pockets were seen and there was destruction of bone and impingement on the spinal cord.

Both an open biopsy from a posterior approach and a biopsy of the posterior mediastinal mass from a mediastinoscopy procedure were initially non-diagnostic. The patient underwent decompression laminectomy because of her hemiplegia. At the time of

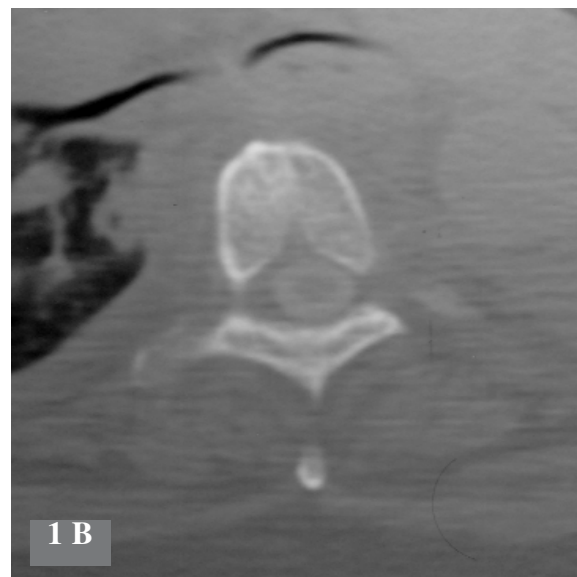
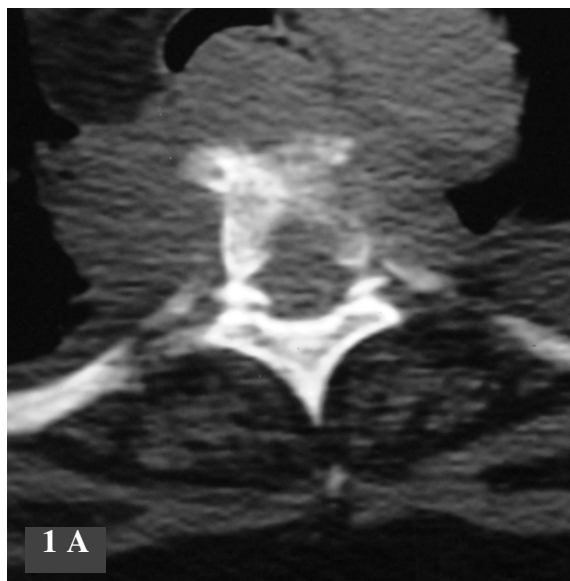


Figure 1 A and 1 B. Axial scans from a thoracic spine CT with intrathecal contrast demonstrating a prevertebral soft tissue mass with vertebral body bone destruction and epidural extension of tumor. Bilateral pleural effusions are present. There is narrowing and encasement of bilateral mainstem bronchi. Abnormal soft tissue also surrounds the descending aorta.

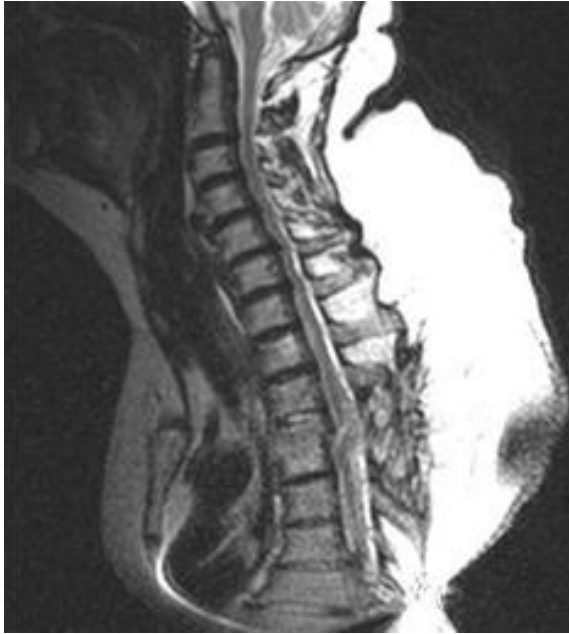

Figure 2. Sagittal T2, with image showing obliteration of T3-4 disc with prevertebral mass involving the posterior element, with changes from T2-3 to T4-5 and a suggestion of local expansion and distortion of cord at the level of surgery. Spinal cord is displaced anteriorly in this image taken five years after surgery.

the operation, a firm mass within the posterior mediastinum was confirmed to have destroyed portions of T3 and T4. The mass was continuous, with the lesion anterior to and lateral to the spine. No instrumentation was placed. Stability has been noted ten years after presentation. (Figure 2) Biopsies were initially felt to represent chronic inflammation; the possibility of a low grade sarcoma (chondrosarcoma or myxoid fibrosarcoma) was raised because of a mass lesion which invaded and compromised the spinal canal. Microscopic specimens showed metaplastic bone and cartilage on a background of a fibrous stroma (Figures 3, 4). Few mitotic figures and no cellular atypia were seen. Tissue stains were negative for bacteria, viral inclusions and fungi. There were no granulomas. No sulfur crystals were seen. Both long-term and short-term cultures were negative for bacteria, fungi and viruses. A Charcot joint, originating in one of the facet joints, was felt to be the best explanation for the painless, destructive mass. The patient has been stable, has lost weight, and is walking short distances with the aid of a walker. Previously the patient had

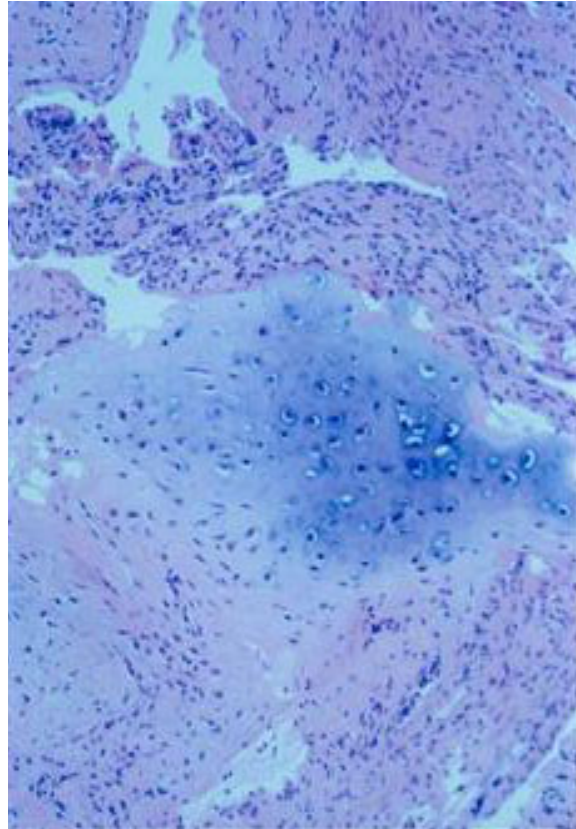


Figure 3. Low power view revealing metaplastic cartilage with acute and chronic inflammatory tissue on the background of a dense, fibroma-like stroma.

worked as a hotel manager, but since the diagnosis of Charcot spinal arthropathy, she has been unable to work.

DISCUSSION

Charcot joint of the spine is a rare diagnosis. Treatment is largely surgical and of a supportive nature. With the growing population of traumatic spinal cord injuries, more Charcot joints of the spine will be diagnosed, and this diagnosis should be in the differential diagnosis of destructive spinal lesions in debilitated patients.

The patient gained a great deal of weight and developed diabetes before presenting with Charcot arthropathy. In many of the patients previously described, an associated traumatic injury resulting in a painless arthropathy and instability led to the development of spinal Charcot joints.^{6,8,10} Unlike the case

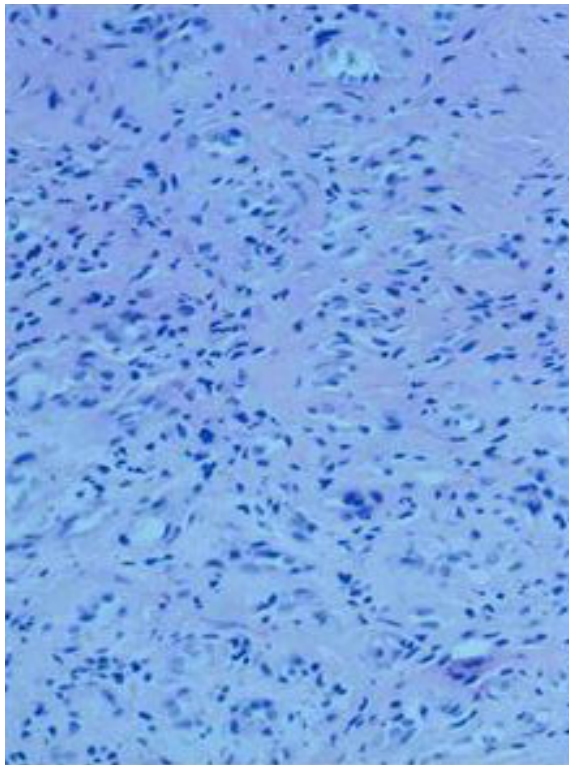


Figure 4. Higher power view reveals dense matrix of chronic inflammation without cellular atypia or other evidence of malignancy.

presented here, many prior cases have required more extensive surgery, including anterior and posterior stabilization procedures and reconstruction with hardware.¹⁻¹¹ Most cases of true Charcot arthropathy do, however, require stabilization. Currently, the patient is doing well, with some residual lower extremity weakness and diet-controlled diabetes mellitus. We believe our case illustrates the importance of having this uncommon entity in the differential diagnosis of a spinal cord mass with associated destruction of the vertebral body. Though it may appear to be a low-grade musculoskeletal tumor on initial pathologic examination, it is not, of course, a neoplasm and hence treatment is primarily surgical and does not involve chemotherapy or radiation therapy. Charcot arthropathy of the spine mimics soft tissue tumors both by appearing as a destructive mass lesion on radiographic studies, and histologically by appearing to show low grade malignancy, suggesting either a low grade chondrosarcoma or a low grade fibrosarcoma.

REFERENCES

1. Brown, CW, Jones B, Donaldson DH, Akmakjian J, Brugman JL. Neuropathic (Charcot) arthropathy of the spine after traumatic spinal paraplegia. *Spine* 17(Suppl): S103-S108, 1992.
2. Fidler WK, Dewar CL, Fenton PV. Cervical spine pseudogout with myelopathy and Charcot joints. *J Rheumatol* 23: 1445-1448, 1996.
3. Guille, JT, Forlin E, Bowen R. Charcot joint disease of the shoulders in a patient with anhidrosis: A case report. *J Bone Joint Surg Am* 74: 1415-1417, 1992.
4. Heggeness MH. Charcot arthropathy of the spine with resulting paraparesis developing during pregnancy in a patient with congenital insensitivity to pain. *Spine* 19: 95-98, 1993.
5. Ingram CM, Harris MB, Dehne, R. Charcot spinal arthropathy in congenital insensitivity to pain. *Orthopedics* 19: 251-255, 1996.
6. McBride GG, Greenberg D. Treatment of Charcot spinal arthropathy following traumatic paraplegia. *J Spinal Disord* 4: 212-220, 1991.
7. McCann PD, Herbert J, Feldman F, Kelly MA. Neuropathic arthropathy associated with neurofibromatosis. *J Bone Joint Surg Am* 74: 1411-1414, 1992.
8. Montgomery TJ, McGuire RA, Jr. Traumatic neuropathic arthropathy of the spine. *Orthop Rev* 22:1153-1157, 1993.
9. Pritchard JC, Coscia MF. Infection of a Charcot spine. *Spine* 18: 764-767, 1993.
10. Schwartz HS. Traumatic Charcot spine. *J Spinal Disord* 3: 269-275, 1990.
11. Werner JG Jr, Holt RT. Neuropathic spinal arthropathy: A case history and six year follow-up. *J Ky Med Assoc* 93: 48-52, 1995.

Correspondence

Russell Patrick GOLLARD, MD FACP
 Cancer & Blood Specialists of Nevada
 58 N. Pecos Road
 Henderson, NV 89074
 USA

Phone: (+1-702) 822-2000

e-mail: rgollard@hotmail.com