

Upper Gastrointestinal Bleeding as Initial Presentation of Burned-out Testicular Tumor

Haldun KAR¹, Erdinc KAMER¹, Nese EKINCI², Cengiz GIRGIN³,
Mehmet A. ONAL¹, Murat ERMETE²

¹ Atatürk Training and Research Hospital, Clinics of 4th General Surgery

² Atatürk Training and Research Hospital, Clinics of 2nd Pathology

³ Atatürk Training and Research Hospital, Clinics of 1st Urology, Izmir, TURKEY

ABSTRACT

We report a case of 33-year-old man who initially presented with upper gastrointestinal bleeding caused by metastatic testicular cancer. Physical examination was significant for a palpable abdominal mass. Emergency gastroduodenoscopy yielded an ulcerated infiltrating mass in the third portion of the duodenum. Computerized tomography of the abdomen demonstrated a retroperitoneal mass. Histological examination of the retroperitoneal mass biopsy showed a nonseminomatous germ cell tumor consisting of embryonal cell carcinoma. Examination of the testes revealed a normal-sized firm left testis, and a normal right one. Ultrasonography of the testes showed multiple left testicular calcifications. The patient underwent left radical inguinal orchiectomy and histological examination of the resected testis showed spontaneous regression of testicular germ cell tumor. We suppose that the tumor was a so-called 'burned-out' testicular tumor. He was treated with four courses of chemotherapy with cisplatin, etoposide and bleomycin. At five year follow-up, the patient was doing well, with no recurrences.

Keywords: Burned-out, Gastrointestinal bleeding, Metastatic testicular neoplasm, Testicular germ cell tumor

ÖZET

İlk Bulgusu Üst Gastrointestinal Sistem Kanaması Olan Burned-out Testis Tümörü

Bu çalışmada, ilk şikayeti metastatik testiküler kanser nedeniyle üst gastrointestinal kanama olan 33 yaşında erkek hastayı sunduk. Fizik muayenede belirgin batında belirgin kitle mevcuttu. Acil endoskopide duodenum 3. kıtada ülserle infiltratif kitle izlendi. Batın tomografisinde retroperitoneal kitle tespit edildi. Retroperitoneal biyopsinin histolojik incelemesinde embriyonel hücreli karsinomadan oluşan nonseminomatöz germ hücreli tümör saptandı. Skrotal muayenede sol testis normal boyutlarda olup sert kıvamda, sağ testis ise normal palpe edildi. Testis skrotal ultrasonunda sol testiste multiple kalsifikasyonlar saptandı. Hastaya sol radikal inguinal orşiektomi uygulandı ve rezeke edilen testisin histolojik incelenmesinde testiküler germ hücreli tümörün spontan regresyone olduğu görüldü. Tümörün burned-out testiküler tümör olduğu kanısına varıldı. Dört kür cisplatin, etoposide, bleomycin kemoterapisi sonrası 5 yıldır kontrolde olan hastada rekürrens saptanmadı.

Anahtar Kelimeler: Burned-out, Gastrointestinal kanama, Metastatik testiküler neoplazm, Testisin germ hücreli tümörü

INTRODUCTION

Burned-out testicular tumor of the testis is a rare clinical entity. It generally presents with metastases and is nonpalpable during testicular examination. Immunological and ischemic causes have been suspected to play a role in its etiopathogenesis.^{1,2} Diagnosis is often difficult because primary lesion may not be found initially. Fewer than 5% of the patients with metastatic testicular cancer present with gastrointestinal (GI) involvement.^{3,4,5} Testicular burned-out tumor with GI involvement is even rarer with only a few reported cases in the English literature. We present a case of testicular burned-out tumor having retroperitoneal lymph node metastases which has caused upper GI bleeding.

CASE REPORT

A 33-year-old previously healthy man presented emergency room complaining of epigastric pain, fatigue and weakness. Physical examination was significant for a palpable abdominal mass. Laboratory analysis revealed WBC: 13.6/mm, Hgb: 9.6 g/dl, Hct: 31.8%. Stool was heme positive. Emergency gastroduodenoscopy yielded an ulcerated infiltrating mass in the third portion of the duodenum causing narrowing of the lumen. Biopsy of the ulcer lesion confirmed undifferentiated carcinoma. Computerized tomography (CT) of the abdomen demonstrated a retroperitoneal mass located between the tail of the pancreas and iliac wing. Left psoas muscle was infiltrated by the mass (Figure 1). The patient underwent emergency laparotomy with signs of acute abdominal pain on the second day of hospitalization. Exploration of the abdomen revealed a (10 x 10 cm) retroperitoneal mass extending into the mesentery of the small intestines. The mass was considered unresectable and incisional biopsies were obtained. As bile leak developed on the 2nd postoperative day, oral fluid intake was stopped. Octreotide treatment and total parenteral nutrition were initiated. Bile leak ceased on the 12th postoperative day. Histological examination of the retroperitoneal biopsy showed a nonseminomatous germ cell tumor consisting of embryonal cell carcinoma. Microscopically, the tissue was completely neoplastic which was mainly solid with foci of haemorrhage and necrosis. Sheets of cells with typical large, irregular shaped nuclei and prominent nucleoli formed rare papillary and glandu-

lar formations that was considered as embryonal cell carcinoma (Figure 2). Immunohistochemical stain for alpha-fetoprotein (AFP) was positive within the tumor cells. Additional history of spontaneous regression of a left scrotal swelling which had occurred one year before surgery was obtained. The patient had received antibiotic treatment with the diagnosis of epididymitis and also received treatment for infertility (human chorionic gonadotropin 5000 IU for 6 weeks). Histopathological results and urogenital history of the patient necessitated consultation of an urologist. Examination of the testes revealed a normal-sized but firm left testis without pain on palpation, and a normal right testis. Scrotal ultrasonography (SUS) showed multiple left testicular calcifications and an enlarged epididymis. The tumor markers AFP and beta-human chorionic gonadotropin (β -HCG) were 225 ng/mL (0-8 ng/mL), and 43.7 IU/L (<10 IU/L), respectively. CT scan of the chest was normal. The patient underwent left radical inguinal orchiectomy and histological examination of the resected testis showed spontaneous regression of testicular germ cell tumor (GCT). Grossly, there was a well-delimited nodular scar tissue which was 1 cm in diameter. Microscopically, this scar tissue was made up of ghost tubules with scattered hemosiderin laden macrophages, coarse intratubular calcifications and atrophic tubules in a hyalinised background. Interestingly, there was intratubular germ cell neoplasia of unclassified type (IGCNU) in the seminiferous tubules peripheral to the area of nodular scarring (Figure

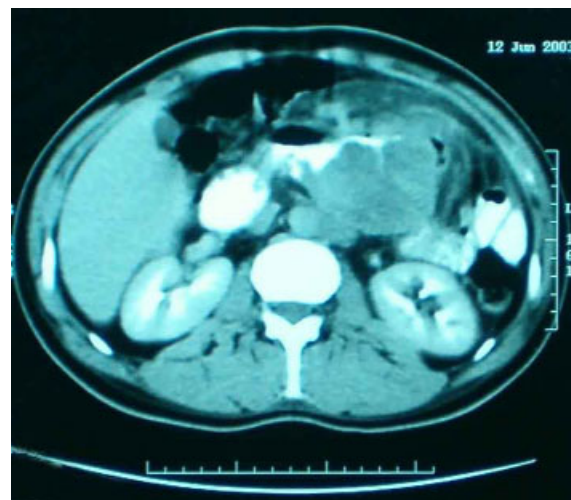


Figure 1. CT scan of the abdomen showed a retroperitoneal mass.

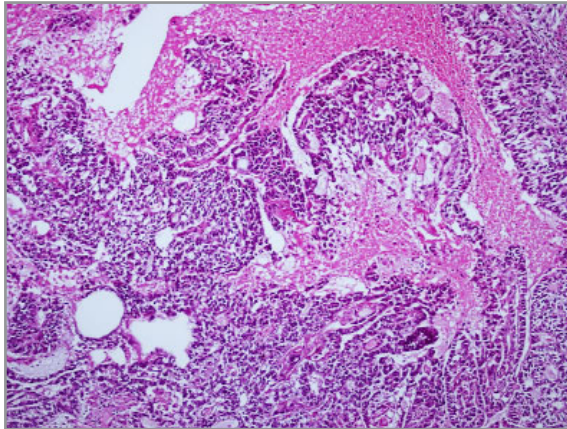


Figure 2. Sheets of cells forming papillary and glandular formations.

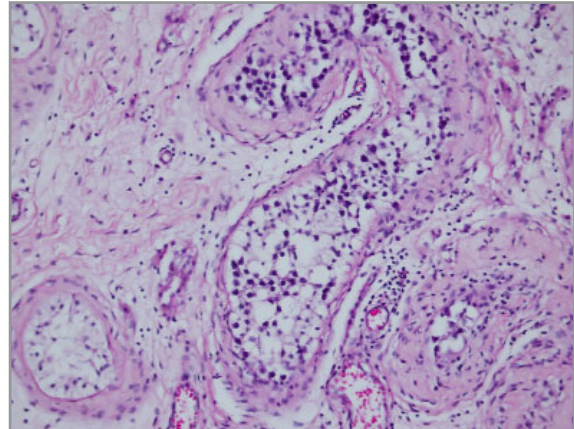


Figure 3. Intratubular germ cell neoplasia of unclassified type in the seminiferous tubules peripheral to the area of nodular scarring.

3). Neoplastic cells were placental alkaline phosphatase (PLAP) positive. He was treated with four cycles of standard BEP protocol consisting of bleomycin, etoposide, and cisplatin. Complete response was achieved. The patient was followed-up for 5 years and he was well without any recurrence on his last follow-up visit.

DISCUSSION

Testicular cancer is the most common malignancy in men aged 20 to 35 years and accounts for approximately 1% of all male malignancies.⁶ GCTs of the testis can be divided into two major subgroups based on histological findings: seminoma and nonseminoma. Nonseminomatous germ cell tumors (NSGCT) consist of embryonal cell carcinoma, yolk sac tumor, choriocarcinoma, and teratoma and frequently present during the third decade of life. Metastatic disease has been detected at presentation in 50% of patients with NSGCT.⁶

At initial presentation, symptoms manifesting secondary to metastatic disease occur in approximately 20% of patients and include a mass in the left neck, pulmonary complaint such as hemoptysis or dyspnea, abdominal mass, or back pain that can often be disabling.⁶ Anemia due to chronic blood loss, intestinal obstruction, and massive gastrointestinal bleeding with haematemesis or melena are most common manifestations of GI tract invasion.⁷ The latter was our patient's initial presentation due to GI tract invasion.

Lymphatic spread is common to all forms of GCT.⁶ Metastases to the gastrointestinal tract occur by either direct tumor extension from affected lymph nodes or hematogenous spread. The anatomical relationship between the involved retroperitoneal lymph nodes and the duodenum may account for the high frequency of duodenal involvement.^{3,5}

Germ cell tumor diagnosis is done by endoscopic and/or percutaneous biopsies in most cases with a retroperitoneal mass and GI disturbances. Metastatic testicular cancer or extragonadal GCT are the two possibilities in such a case. Most patients with metastatic testicular cancer have a palpable testicular mass while a few cases do not. Since a primary tumor of testicular origin may exist in the extragonadal GCT, it is important to examine the intrascrotal contents in detail in the case of so-called extragonadal germ cell tumors with palpable normal testes. In such cases, there are two possible conditions, an occult testicular tumor and a burned-out testicular tumor.⁸

The term "burned-out" tumor of the testis describes a spontaneously and completely regressed testicular tumor, which present at the stage of metastases. These metastases may involve retroperitoneal, mediastinal, supraclavicular, cervical, and axillar lymph nodes, lungs and liver.^{1,2} In this condition SUS is crucial in detecting the regressed tumor. SUS may reveal a hypoechoic mass and microcalcifications.² SUS also showed microcalcifications in our case. This finding is in agreement with three of five patients that was reported by Fabre et al.² Also the serum tumor

markers AFP, β HCG, and lactat dehydrogenase (LDH) have a clear role in both diagnosis and clinical management of testicular GCT. Elevation of one or more markers occurs in 80% of metastatic GCT of the testis.⁶ SUS and tumor marker assays should be performed systematically in the presence of retroperitoneal adenopathy with normal testicular clinical examination.

Schmoll et al. noted that in case of a histologically poor or undifferentiated carcinoma, presence of a GCT comes into one's mind. They also emphasized that immunohistochemical evaluation, including germ cell specific markers, must be done for such histologies.⁹ The initial biopsy obtained from the duodenum of the present case had been interpreted as undifferentiated carcinoma, but immunohistochemical tests had not been performed because of insufficient volume of the biopsy.

Balzer et al. reported that among the features analyzed in their study, IGCNU in a scarred testis was the single most specific one for GCT regression. They accepted the presence of IGCNU in combination with testicular scarring and atrophy as diagnostic evidence of GCT regression, even in the absence of known metastatic GCT.¹⁰

In conclusion, although gastrointestinal bleeding is a negative prognostic sign for metastatic testis tumors, early diagnosis and treatment of retroperitoneal nodal metastases decreases mortality. Primary and extragonadal germ cell tumors should be included in differential diagnosis in a young male patient presenting with an abdominal mass and anemia due to GI bleeding. Clinical examination of the testis is not sufficient to eliminate a primary testicular tumor. Cases without a palpable testicular mass should be evaluated with SUS and appropriate tumor markers to rule out a burned-out testicular tumor.

REFERENCES

1. Kebapci M, Can C, Isiksoy S, et al. Burned-out tumor of the testis presenting as supraclavicular lymphadenopathy. *Eur Radiol* 12: 371-373, 2002.
2. Fabre E, Jira H, Izard V, et al. 'Burned-out' primary testicular cancer. *BJU Int* 94: 74-78, 2004.
3. Altamar HO, Middleton GW, Capozza TA, et al. Profound anemia from duodenal invasion of metastatic testicular seminoma. *J Urol* 171: 344-345, 2004.

4. Rosenblatt GS, Walsh CJ, Chung S. Metastatic testis tumor presenting as gastrointestinal hemorrhage. *J Urol* 164: 1655, 2000.
5. Shariat SF, Duchene D, Kabbani W, et al. Gastrointestinal hemorrhage as first manifestation of metastatic testicular tumor. *Urology* 66: 1319, 2005.
6. Carver BS, Sheinfeld J. Germ cell tumors of the testis. *Ann Surg Oncol* 12: 871-880, 2005.
7. Syrigos KN, Tsioulos D, Efstathiou S, et al. Metastatic testicular cancer with massive gastrointestinal haemorrhage as initial presentation. *Clin Oncol (R Coll Radiol)* 14: 179-181, 2002.
8. Kitahara K, Hori J, Tokumitsu M, et al. Retroperitoneal germ cell tumor with testicular calcification indicating tiny testicular origin: consideration of the origin of retroperitoneal germ cell tumors: report of two cases. *Hinyokika Kyo* 49: 291-295, 2003.
9. Schmoll HJ, Souchon R, Krege S, et al. European consensus on diagnosis and treatment of germ cell cancer: a report of the European Germ Cell Cancer Consensus Group (EGCCCG). *Ann Oncol* 15: 1377-1399, 2004.
10. Balzer BL, Ulbright TM. Spontaneous regression of testicular germ cell tumors: an analysis of 42 cases. *Am J Surg Pathol* 30: 858-865, 2006.

Correspondence

Dr. Haldun KAR
İtokent Sitesi No: 25 / 23
İçmeler Mahallesi
35430 Urla, İZMİR / TURKEY

Tel: (+90.232) 244 44 44
Fax: (+90.232) 24315 30
e-mail : haldunkar@hotmail.com